

Electron microscopic study of Harderian gland of tropical bird Indian jungle bush quail *Perdica asiatica*

Sunanda Dubey¹, Rakesh Verma² and Chandana Haldar^{2*}

¹Department of Zoology, Udai Pratap Autonomous Degree College,
Bhojpur, Varanasi-221002, India.

²Pineal Research Laboratory, Department of Zoology, Banaras Hindu University,
Varanasi-221005, India.

Summary

The structure of Harderian gland (HG) of tropical avian species has never been studied in detail. In the present study we investigated the structure of HG of a tropical avian species adopting light- and transmission electron microscopy. HG from both male and female adult birds, *P. asiatica* (N=5 each sex) were studied from light microscopic (hematoxylin-eosin staining) and transmission electron microscopic perspectives. The tubulo-alveolar HG of *P. asiatica* did not reveal any sexual dimorphism as reported in other birds. The HG of this bird is encapsulated by thick connective tissue consisting of collagen fibers, nerve fibers and blood vessels. HG lobules are lined with columnar epithelial cells. Plasma cells are found in interlobular spaces. The columnar epithelial cells are secretory in nature and have both rough and smooth endoplasmic reticula surrounding the nucleus when observed in transmission electron microscope. There is active Golgi apparatus with dilated cisternae. Mitochondria are well developed, with elongated cristae, and are scattered throughout the cytoplasm along with abundant free ribosomes. Lipid droplets are present in the cytoplasm along with two types of materials, electron-luscent and electron-dense. We could trace the various stages of synthesis of the secretory material for merocrine release. Thus, the light microscopic and ultrastructural organization of HG of *P. asiatica* have been elucidated.

Keywords : Bird, Indian jungle bush quail, Harderian gland, secretory acini.

Introduction

The Harderian gland (HG) is a tubulo-alveolar gland located within the ocular orbit, positioned medial and posterior to the eyeball in animals that possess nictitating membrane (Boydak and Aydin, 2009). The gland was first described by the Swiss physician Johann Jacob Harder in 1964 in the deer *Dama vulgaris*. The HG may be compound tubular (Schwarz-Karsten, 1937; Bloom and Fawcett, 1975) or compound tubulo-alveolar (Sabry and Al-Ghaith, 2000; Ortiz et al., 2007), indicating that the gland contains a branched duct system and tubular alveoli (Sakai, 1981). HG is the major exocrine-paracrine gland (Mobini, 2012). Recently, histological and histochemical studies have been carried out on HG in avian species (Ohshima and Hiramatsu, 2002; Dimitrova and Nikiforov, 2005). However, the detailed electron-microscopic structure of HG of any tropical bird has never been reported earlier. Therefore, the present investigation was carried out for the first time to study the fine structure of HG of the tropical bird Indian jungle bush quail, *Perdica asiatica*.

Materials and methods

Maintenance of animals

Adult male and female (possessing complete keratinized beaks) Indian jungle bush Quail, *P. asiatica* (body weight 45 ± 5 g), were collected from the vicinity of Varanasi (Lat. $25^{\circ}18'N$; Long. $83^{\circ}01'E$) and acclimated to aviary conditions for two weeks in an open air aviary having all natural facilities for mating and nesting. The birds were fed with millets (*Pennisetum typhoides*) along with seasonally available grains and water *ad libitum*. After acclimation, birds of both sexes were selected randomly (N=5 for each sex and for both light and electron microscopic studies) and decapitated under anesthesia. HG was immediately dissected out from the eye orbit under aseptic condition and then processed for microscopic study.

Light microscopic (LM) study

HG was fixed in neutral buffered formalin (10%), washed and processed for dehydration followed by

paraffin infiltration. Sections at 5µm thickness were cut using a semiautomatic microtome (Leica Microsystems Inc., USA), stained with hematoxylin and eosin, and observed in a research microscope (Leica MPV-3, Germany) for general histological examinations.

Electron-microscopic (EM) study

The location of HG in eyeball was flooded with a cold fixative consisting of glutaraldehyde (2.5%) in phosphate buffer (0.1M, pH 7.25) maintained at 4°C. HG was then washed with the same phosphate buffer for 20 min, post-fixed in 1% osmium tetroxide prepared in phosphate buffer (0.1M, pH 7.25) maintained at room temperature for 1 h. HG was then dehydrated with graded series of alcohol, and embedded in Epon 812 (Glauert and Glauert, 1958). The ultrathin sections were cut in LKB ultratome III, spread on copper grid, dried and then double-stained with uranyl acetate (Watson, 1958) and lead citrate (Reynolds, 1963). The sections were then examined in a Philips CM 200 transmission electron microscope.

Results

Histological observations of HG

The HG of *P. asiatica* is elongated proximally and bulbous distally. The gland measures 8 mm along the longest axis. There is no discernible sexual dimorphism in the HG. The HG duct system opens within inter-acinar spaces. The discrete lobules of HG are lined by glandular epithelial cells, which release the secretion into a wide lumen. Acini, plasma cells and inter-tubular interstices are common features of HG (Fig. 1).

Electron microscopic observations of HG

The HG of *P. asiatica* is surrounded by a thick adventitial connective tissue capsule. The gland *per se* is divided into lobules of different sizes. The acini lie at the periphery of the lobules and are lined by secretory columnar epithelium. The connective tissue capsule is made up of collagen fibers and fibroblasts, nerve fibers and blood vessels. The secretory columnar epithelial cells consist of prominent nucleus, containing a nucleolus, surrounded by well developed and hypertrophied rough endoplasmic reticulum with dilated well-organized lamellae. Smooth endoplasmic reticulum is also present surrounding the nucleus and the granular endoplasmic reticulum. Free ribosomes are abundantly distributed throughout the cytoplasm. The cytoplasm has large functional Golgi apparatus with stacked and dilated cisternae. Various stages of vesicle formation could be observed around the Golgi apparatus. As the cytoplasm

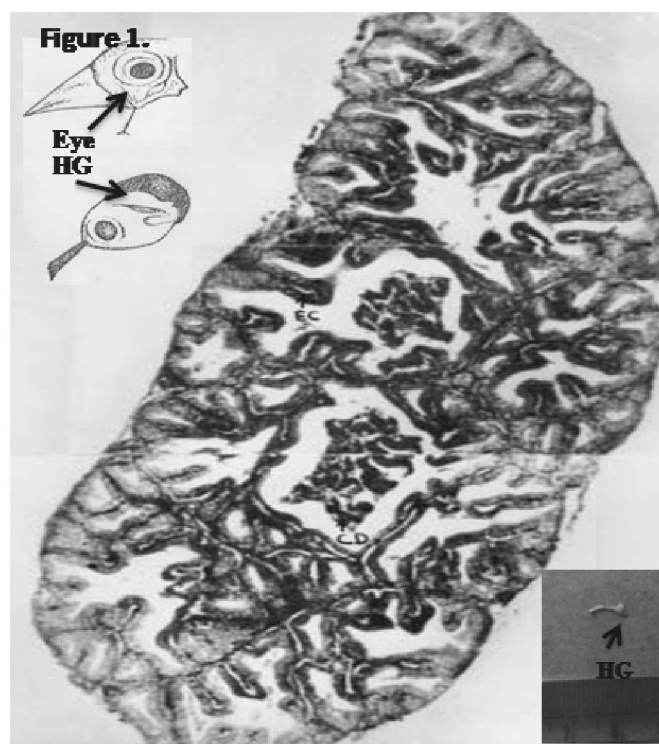


Fig. 1. Diagrammatic representation of Harderian gland (HG) of *P. asiatica* showing the location inside the orbit and a photomicrograph of section of HG showing bundles of acini and columnar epithelial cells. Insert shows an isolated gland.

gets filled with secretory material, the vesicles show tendency to fuse among themselves before discharging the content by fusion with the apical plasma membrane. Mitochondria, scattered throughout the cytoplasm, possess well developed elongated cristae.

Many finger-like projections are seen at the apical face of the cells. Contractile myoepithelial cells are found at the base of the ductal epithelium, close to the basal lamina. The membrane-bound secretory vesicles of different sizes are found to be closely packed and consist of two kinds of secretory materials, electron-opaque and electron-dense. The cytoplasm of secretory cells possesses crystalline structures of unknown function (Fig. 2 A-F).

Discussion

The Harderian gland of mammals exhibits marked sexual differences in cell types and porphyrin production. There are also two types of secretory cell types in the male glands while glands of female have only a single secretory cell type as reported in hamsters (Coto-Montes et al., 1994). It is evident from the present study that there

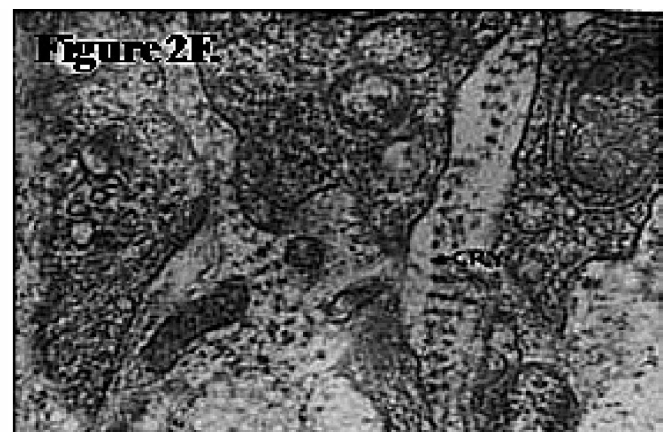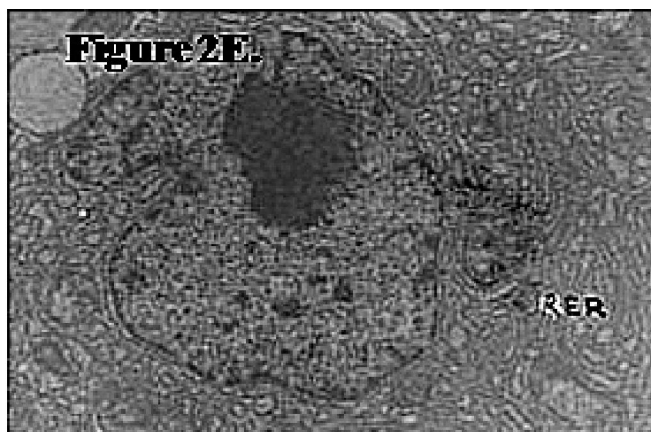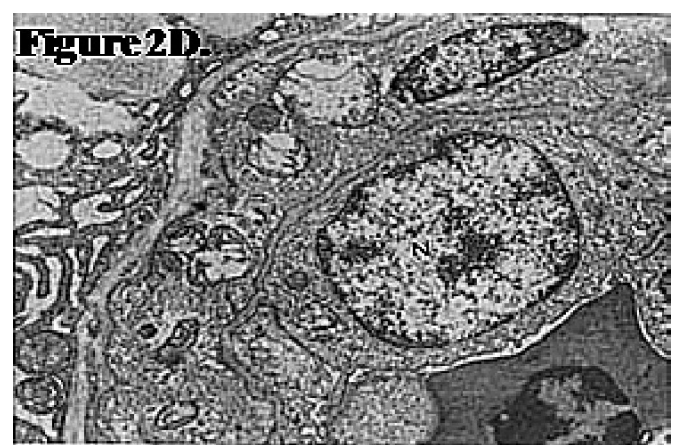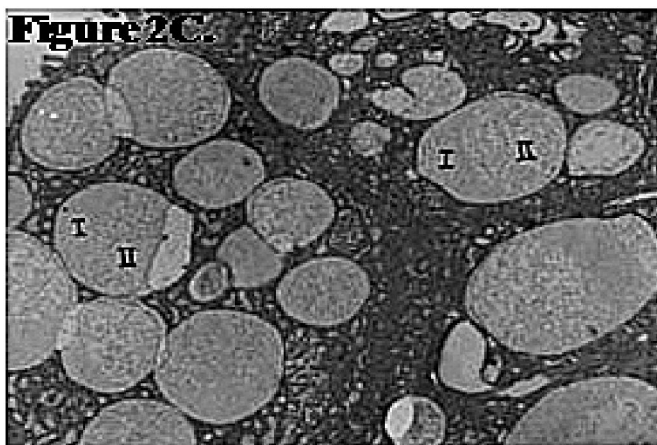
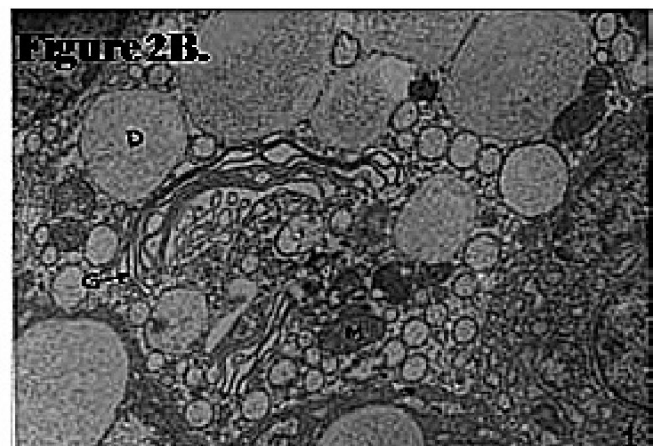


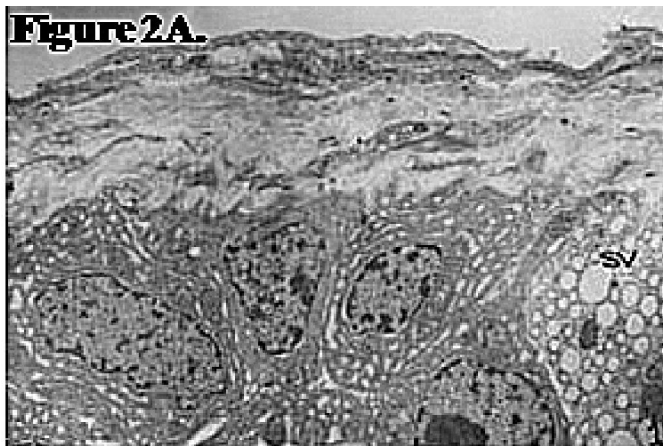Fig. 2. Electron micrographs of HG of *P. asiatica*. **A.** Shows thick outer envelope with epithelial cells and acini lined with cells possessing nuclei with discrete chromatin and cytoplasm with secretory vacuoles (SV). **B.** Extended Golgi (G) zone with dilated cisternae and smooth endoplasmic reticulum (SER), mitochondria (M), and secretory droplets of different sizes (D); **C.** Two different types of vesicles, with electron-dense (I) and electron-luscent (II) material. **D.** Connective tissue-like cell with prominent nucleus (N) and less cytoplasmic inclusions. **E.** Hypertrophied rough endoplasmic reticulum (RER) with lamellae. **F.** Crystalline collagen fibrous structure (CRY). (2A, x8000; 2B-F, x14000).

is no significant difference in the structure of HG on the basis of sex in *P. asiatica* as is the case in domestic geese (Boydak and Aydin, 2009). The HG of *P. asiatica* is colorless, elongated proximally but otherwise bulbous. Histologically the HG is tubulo-alveolar in nature, encapsulated by loose connective tissue (Kozlu et al., 2010), and the septa arising from the connective tissue divide the tissue of the gland into several lobes of various sizes (Mobini, 2012).

The ultrastructural study suggests that HG is predominantly involved in merocrine secretion as there was no evidence of apocrine or holocrine secretion because debris were not noticed in the tubular lumina. The HG of *P. asiatica* has connective tissues, blood vessels, nerve fiber bundles, collagenous substances and reticular fibers, as reported by Boydak and Aydin (2009) in the domestic geese. The luminal lining is composed of columnar epithelial cells of different height depending upon the activity status of HG (Altunay and Kozlu, 2004). Acini lined by columnar epithelial cells contain large secretory droplets forming a flocculent material. The cells possess extended Golgi zone and smooth endoplasmic reticulum with some active mitochondria. The secretory droplets formed two types, with electron-dense and electron-lucent material. Some connective tissue-like cells were also found at the border of the acini. These cells possess large prominent nuclei and less cytoplasmic inclusions and no secretory droplets. The HG contains contractile myoepithelial cells (Cacho et al., 1991) and abundant plasma cells (Scott et al., 1993; Khan et al., 2007). Plasma cells are present in large numbers in the HG of many avian species and this could be the reason why the avian HG has been studied extensively for its immunological functions. Further, Maxwell and Burns (1979) reported

that plasma cells and lymphocytes are present in the ducts of the HG of Turkeys, ducks and chicken. Participation of plasma cells in the aspects of local immune system, especially with regard to the course of the immune response after antigen application or eye inflammation, has been well documented in birds (Khan et al., 2007).

The secretory cells in HG appear to contain apical mucus-containing vesicles and basal aggregation of lipid droplets (Dubey and Haldar, 1997). In birds the established role of HG is to lubricate the surface of eye ball and nictitating membrane (Payne, 1994) while they also serve as source of growth hormone and pheromones (Olcese and Wesche, 1989), and also play role in immune response (Oshima and Hiramatsu, 2002). HG is capable of synthesizing melatonin in mammals (Menendez-Pelaez et al., 1993), and thus would play role in regulation of reproduction under influence of photoperiodic changes in the environment these animals experience. In addition to the role in immunological functions (Oshima and Hiramatsu, 2002), the gland secretes porphyrin pigments ascribed with thermoregulatory role (Thiessen et al., 1982). It could be concluded that the *P. asiatica* HG is a compound tubulo-alveolar gland with secretory epithelial cells, having abundant mitochondria, rich rough endoplasmic reticulum and a complex network of Golgi elements, myoepithelial cells and plasma cells.

Acknowledgments

Authors thank Council of Scientific & Industrial Research (CSIR), New Delhi, for the Junior Research Fellowship (JRF) to RV. Kind help of Prof. B. Vigh, Semmelweis University, in TEM study is gratefully acknowledged. Equipment grant by Alexander von Humboldt (AvH) to CH is also acknowledged.

References

- Altunay H, Kozlu, T. (2004) The fine structure of the Harderian gland in the ostrich (*Struthio camelus*). *Anat Histol Embryol.* **33**: 141–145.
- Bloom W, Fawcett DW. (1975) *A Textbook of Histology*. 10th ed. Philadelphia: W B Saunders.
- Boydak M, Aydin MF. (2009) Histology of the Harderian gland of domestic geese (*Anser anser domesticus*). *Acta Vet Brno.* **78**: 199–204.
- Cacho ED, Gallego M, Felices C, Bascuas JA. (1991) Myofibroblasts and myoepithelial cells in the chicken Harderian gland. *Histol Histopathol.* **6**: 303–308.
- Coto-Montes A, Masson-Pevet M, Pevet P, Moller M. (1994) The presence of opioidergic pinealocytes in the pineal gland of the European hamster (*Cricetus cricetus*): an immunocytochemical study. *Cell Tissue Res.* **278**: 483–491.

- Dimitrov DS, Nikiforov IP. (2005) Histological and histochemical studies of Harderian gland, lacrimal gland and bursa of Fabricius in mallard ducks (*Anas sterilis*) with chlamydial infection. *Bulgarian J Vet Med.* **8**: 119–127.
- Dubey S, Haldar C. (1997) Environmental factors and annual Harderian-pineal-gonadal interrelationship in Indian jungle bush quail *Perdicula asiatica*. *Gen Comp Endocrinol.* **106**: 17-22.
- Glauert AM, Glauert RH. (1958) Araldite as an embedding medium for electron microscopy. *J Biophys Biochem Cytol.* **4**: 191-194.
- Khan MZI, Jahan MR, Islam MN, et al. (2007) Immunoglobulin (Ig)-containing plasma cells in the Harderian gland in broiler and native chickens of Bangladesh. *Tissue Cell.* **39**: 141-149.
- Kozlu T, Bozkurt YA, Altunay H, Sari EK. (2010) Histological and histochemical studies on the Harderian gland of the osprey (*Pandion haliaetus*). *J Anim Vet Adv.* **9**: 1875–1879.
- Maxwell MH, Burns RB. (1979) The ultrastructure of the epithelium of the ducts of the Harderian and lacrimal glands of the Turkey, fowl and duck. *J Anat.* **128**: 445-459.
- Menendez-Pelaez A, Rodriguez C, Buzzell GR, Reiter RJ (1993) Melatonin and its synthetic enzymes in orbital glands. In: Yu SH, Reiter RJ (Eds). *Melatonin: Biosynthesis, Physiological Effects, and Clinical Applications.* pp. 395-415. Boca Raton, FL, USA: CRC Press.
- Mobini B (2012) Histological and histochemical studies on the Harderian gland in native chicken. *Vet Med.* **57**:404-409.
- Ohshima K, Hiramatsu K. (2002) Immunohistochemical localization of three different immunoglobulin classes in the Harderian gland of young chicken. *Tissue Cell.* **34**: 129-133.
- Olcese J, Wesche A. (1989). The Harderian gland. *Comp Biochem Physiol.* **93**: 655–665.
- Ortiz GG, Feria-Velasco A, Tarpley RL, et al. (2007) The orbital Harderian gland of the male Atlantic Bottlenose Dolphin (*Tursiops truncatus*): A morphological study. *Anat Histol Embryol.* **36**: 209-214.
- Payne AP. (1994) The Harderian gland: A tercentennial review. *J Anat.* **185**: 1–49.
- Reynolds ES. (1963) The use of lead citrate at high pH as an electron-opaque stain in electron microscopy. *J Cell Biol.* **17**: 208-212.
- Sabry I, Al-Ghaith L. (2000) The Harderian gland of the Dhub lizard *Uromastix microlepis* of the Kuwaiti desert: an ultrastructural approach. *Tissue Cell.* **32**: 71-78.
- Sakai T. (1981) The mammalian Harderian gland: morphology, biochemistry, function and phylogeny. *Arch Histol Jpn.* **44**: 299-233.
- Schwarz-Karsten H. (1937) Über die orbitaldrüsen von *Lacerta agilis*, *Lacerta muralis*, *Ophisops elegant*, *Tarentola mauretana* und *Tropidonotus natrix*. *Morphol Jahrb.* **80**: 248-279.
- Scott TR, Savage ML, Olah I. (1993) Plasma cells of the chicken Harderian gland. *Poultry Sci.* **72**: 1273–1279.
- Thiessen DD, Pendergrass M, Harriman AE. (1982) The thermoenergetics of coat colour maintenance by the Mongolian gerbil, *Meriones unguiculatus*. *J Thermal Biol.* **7**: 51-56.
- Watson MH. (1958) Staining of tissue sections for electron microscopy with heavy metals. *J Biophys Biochem Cytol.* **4**: 475-478.

