

Effects of follicle stimulating hormone (FSH) on the regressed testes of the snake *Enhydris enhydris* (Schneider)

R.N. Jadhav¹ and A.S. Padgaonkar²

¹Department of Zoology, E.S.A.College of Science, Vasai Road 401202, Maharashtra, India

²E/2 Sagar Vaibhav Society, Dahisar, Mumbai 400068, India.

Summary

Administration of FSH (1IU/day) to the snake *Enhydris enhydris* for 14, 28 and 42 days resulted in increase in diameter of the seminiferous tubules of the regressed testes. Proliferation of spermatogonia and increase in abundance of primary spermatocytes were also observed. But the treatment failed to induce the spermatogenic cells to meiotic division. The interstitial cells in the testes between control and FSH-treated snakes did not show any difference. The failure to complete the process of spermatogenesis after FSH treatment indicates that role by a second hormone is necessary for the completion of spermatogenic process. The second hormone may be either LH or androgen.

Key words : FSH, snake, testes.

Introduction

The dependence of reptilian testes on the pituitary has been adequately demonstrated in snakes and lizards, adopting hypophysectomy and replacement therapy during the breeding season (Ceislak, 1945; Pandha and Thapliyal, 1964; Licht, 1968; Reddy and Prasad, 1970). FSH is known to stimulate spermatogenesis in the vertebrates. However, very little work has been done on the effects of purified mammalian gonadotropins in snakes (Padgaonkar and Samuel, 1993; Jadhav and Padgaonkar, 2000). Hence, the present study was undertaken to find the effects of follicle stimulating hormone (FSH) on the regressed testes of the estuarine snake *Enhydris enhydris*.

Materials and Methods

The experiments were carried out during the regressed state of gonads of the snake, *Enhydris enhydris* (April and May) (unpublished observation). The snakes were acclimated to the laboratory conditions of temperature and photoperiod for one week prior to the experiments. Male snakes of roughly same length and weight were kept into six different groups each consisting of five animals. Three groups formed the experimental animals while the remaining three groups formed the controls. The snakes in the experimental groups were administered through intra-peritoneal route FSH at 1 IU/day/animal

(Gonadotropon FSH, Paines and Byren, England- Batch No 769007) for 14 (Group 1), 28 (Group 2) and 42 (Group 3) days. The control animals (Groups 4, 5 and 6) received saline (0.02 ml/day/animal) by the same route over the same period of time as their counterparts in the experimental groups. All the animals were sacrificed 24 hr after the last injection under an overdose of sodium pentobarbital anesthesia. The snakes were dissected and both the testes were carefully removed and fixed in Bouin's fluid. Tissues were embedded in paraffin wax, sectioned at 5 µm thickness and stained with hematoxyline and eosin for histological observation. The diameters of more or less transversely cut seminiferous tubules were measured with the help of an ocular micrometer (1cm x 100).

Results

The testes of control animals in groups 4, 5 and 6 revealed complete regression (Fig. 1). The diameter of the seminiferous tubules was much reduced (Table 1). The seminiferous epithelium showed only a single layer of spermatogonia. The diameter of the seminiferous tubules of snakes in the experimental groups 1, 2 and 3 increased (Table 1). The seminiferous epithelium was hypertrophied (Fig. 2). Moreover, as a result of rapid multiplication of spermatogonia, the cell population in the seminiferous tubules of the experimental animals also increased considerably. The effect of FSH administration

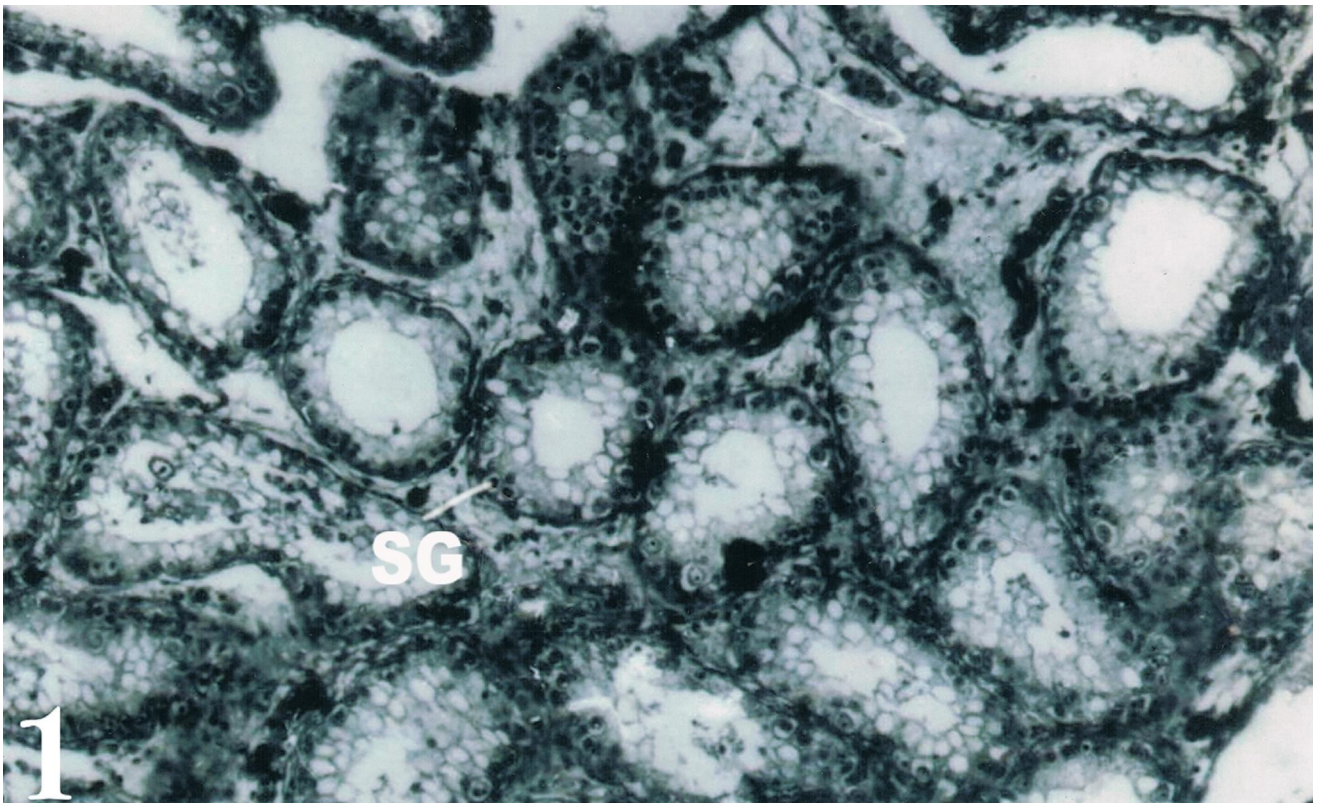


Fig. 1. Transverse section of the testis of control snake during the regressed phase. x 100.

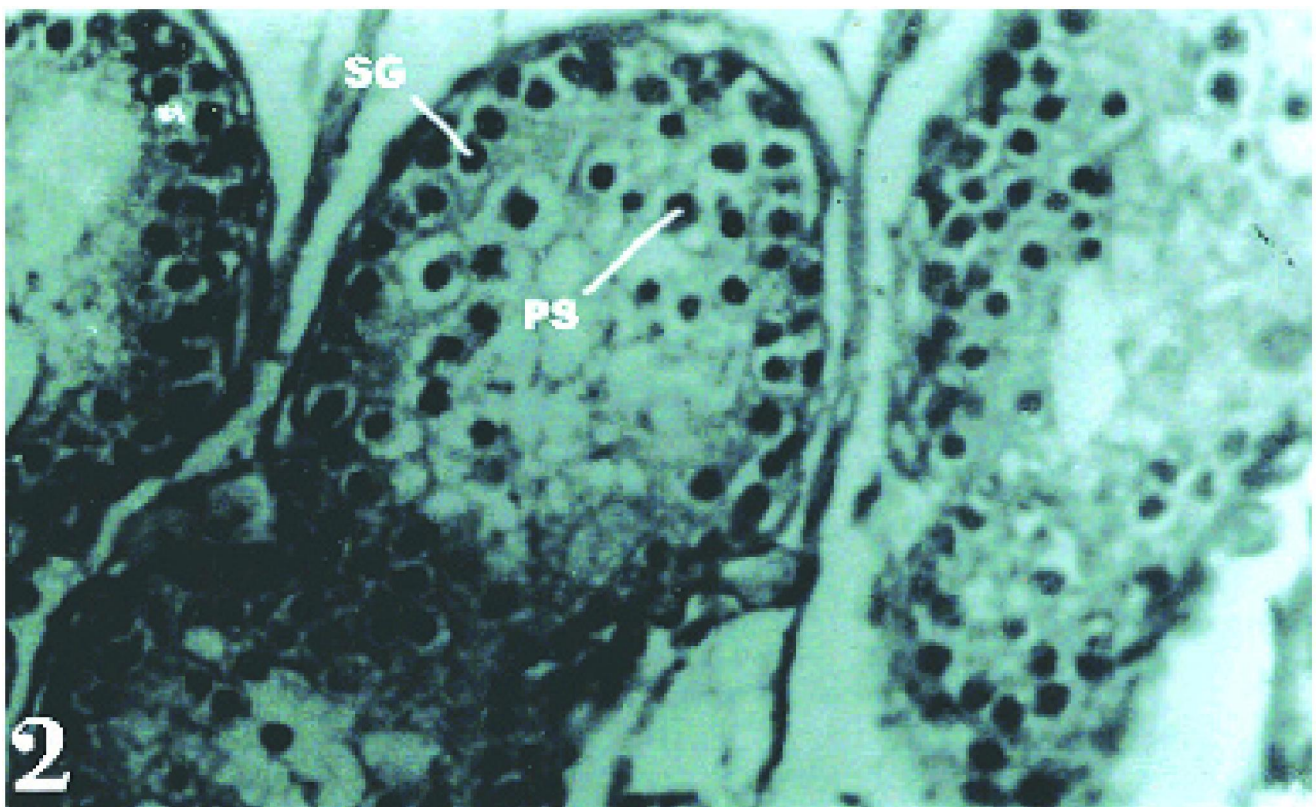


Fig. 2. Transverse section of the testis of snake after 42 days of FSH administration. x400. SG, spermatogonia; PS, primary spermatocytes

Table 1. Effect of FSH administration on the mean diameter of seminiferous tubules of the snake *Enhydryis enhydryis*. Values are mean \pm SD of five animals each.

	Mean seminiferous tubule dia (μ m) after 14 days of treatment	Mean seminiferous tubule dia (μ m) after 28 days of treatment	Mean seminiferous tubule dia (μ m) after 42 days of treatment
Control	68.35 \pm 1.38	69.51 \pm 1.93	70.25 \pm 2.51
Experimental	74.41 \pm 2.64	75.63 \pm 0.36	92.36 \pm 7.92

became evident on the 14th day of treatment itself. The animals treated for 42 days showed maximum development with enlarged seminiferous tubules.

It is to be noted that the spermatogenic process in the treated animal did not proceed beyond the formation of primary spermatocytes (Fig. 2). Thus, FSH administration resulted in proliferation of the spermatogonia and their development up to primary spermatocyte stage, and not beyond, i.e., to stages which depend on reduction division. Thus it appears that the degree of response of FSH is directly proportional to the duration of treatment. A comparison of the interstitial cells of the testis of the control and treated snakes did not reveal any difference.

Discussion

It is an established fact that in mammals the two gonadotropins, FSH and LH, have distinct roles in the process of spermatogenesis. FSH stimulates spermatogenesis, while LH controls development and function of the interstitial cells of Leydig and, thus, it is responsible for the production of androgens. The responsiveness of testis to mammalian FSH differs in the other non-mammalian vertebrates.

Reddy and Prasad (1970) studied the effect of gonadotropins (FSH, LH, PMSG and HCG) and testosterone on the initiation of spermatogenesis in the Indian hypophysectomized house lizard *Hemidactylus flaviviridis* during the non-breeding season. They found that both ovine FSH and PMSG initiated spermatogenesis leading to the formation of mature spermatozoa after 42

days; while LH, HCG or TP had to stimulatory effect on testes. It was concluded from this experiment that the initiation of spermatogenic and androgenic functions in the testes of *Hemidactylus flaviviridis* are dependent on FSH-like protein. On the other hand, Licht and Pearson (1969) have shown that both ovine FSH and LH stimulate spermatogenesis and interstitial activity in the physiologically hypophysectomized lizard *Anolis carolinensis*.

Earlier studies concerning the effect of exogenous administration of pituitary gonadotropins have employed crude pituitary extract or pregnancy urine which contains both FSH and LH. Therefore, it is likely that stimulation of spermatogenesis by FSH observed in these reptilian species may be due to the combined effect of FSH and LH. The failure of completion of spermatogenesis after FSH treatment alone in the snake *Enhydryis enhydryis* indicates that participation of a second hormone, in addition to FSH, is necessary for the completion of the spermatogenic process. This second hormone may be either LH or androgen. This conclusion is in agreement with Kulkarni (1970), Padgaonkar and Samuel (1993) and Jadhav and Padgaonkar (2000), who also expressed a similar view after FSH treatment to the lizard *Calotes versicolor* and the snakes *Acrochordus granulatus* and *Cerberus rhynchops*.

Acknowledgment

The first author (RNJ) is thankful to University Grants Commission (WRO), Pune, for financial assistance (F-No. 47/201/2008-09).

References

- Ceislak SE (1945) Relation between the reproductive cycle and the pituitary gland in the snake *Thamnophis radix*. *Physiol Zool.* **18**:299-329.
- Jadhav RN and Padgaonkar AS (2000) Effects of administration of follicle stimulating hormone (FSH) on the regressed testes of the snake *Cerberus rhynchops* (Schneider). *Trends Life Sci (India)* **15**:19-22.
- Kulkarni P (1970) *Studies on the reproductive cycle and the endocrine glands of the lizard Calotes versicolor* (Boulenger). Ph.D. Thesis. Mumbai, India: University of Mumbai.
- Licht P (1968) Testicular function after partial and total adenohipophysectomy and gonadotropins treatment in the lizard *Anolis carolinensis* (Abstract). *Am Zool.* **8**:119.
- Licht P, Pearson AK (1969) Effects of mammalian gonadotropins (FSH and LH) on the testes of the lizard *Anolis carolinensis*. *Gen Comp Endocrinol.* **13**:367-381.
- Padgaonkar AS, Samuel J (1993). Effects of administration of follicle stimulating hormone (FSH) on the regressed testes of the snake *Acrochordus granulatus* (Schneider). *J Adv Zool.* **14**:44-47.
- Pandha SK, Thapliyal JP (1964) Hypophysectomy in the garden lizard *Calotes versicolor*. *Naturwiss.* **51**:201-202.
- Reddy PRK, Prasad MRN (1970) Effects of gonadotropins and testosterone on the initiation of spermatogenesis in the hypophysectomized Indian house lizard *Hemidactylus flaviviridis* Ruppell. *J Exp Zool.* **174**:205-214.