



Grape Seed and *Physalis* Extracts as Anti-Inflammatory Agents in Cetuximab Induced Tongue Mucositis in Rats

Heba A. Saleh^{1*}, Manar A. Abdul Aziz² and Mona E. Wali³

¹Master degree in Oral and Maxillofacial Pathology, Faculty of Dentistry, Cairo University; Heba_saleh@dentistry.cu.edu.eg

²Oral and Maxillofacial Pathology, Faculty of Dentistry, Cairo University; M.waniss@yahoo.com

³Head of Department of Oral and Maxillofacial Pathology, Faculty of Dentistry, Cairo University; mona.wali@dentistry.cu.edu.eg

Abstract

Background: Oral mucositis induced by cancer therapy alters cancer patient's life. Nutraceuticals these days is for their various activities which could neutralize the toxicity induced by cancer treatment. **Purpose:** Comparison between the effect of grape seed and fruits of *Physalis peruviana* methanol extract in reduction of mucositis induced by Cetuximab drug. **Study Design:** Animal study. **Methods:** 60 male rats divided into 6 groups as 10 in each group. Control group of rats with no intervention given. The other 5 groups were given Cetuximab drug alone or with grape seed extract (simultaneously or 1 week before Cetuximab drug) or *Physalis* extract (simultaneously or 1 week before Cetuximab drug). After sacrifice, tongue was dissected and tissue preparation was done for all samples. Digital counting was done by image analyzer computer system for (a) filiform papillae in H&E stained sections, (b) mast cells in mast cell tryptase stained sections to assess inflammation. The area percent for bax immune-expression in other immune stained sections were also measured done to assess apoptosis. **Results:** The difference between the groups was assessed for statistical significance ($P < 0.0001$) by ANOVA test. The greatest mean number of filiform papillae was recorded in control group I. Greatest mean number of mast cells and the greatest mean area percent of bax immune expression were recorded in group II. **Conclusion:** Grape seed extract and *Physalis* extract could neutralize the harmful effect of cancer therapy. *Physalis* extract had more potent effect in reducing the inflammation induced by Cetuximab drug.

Keywords: Anti-inflammatory Effect, Cetuximab, Mucositis, *Physalis peruviana*

1. Introduction

Cetuximab (Cmab) known as (Erbitux) is a drug used to treat Head and Neck Squamous Cell Carcinoma (HNSCC) with adverse side effects which may change the outcome of treatment¹. It is used as a single agent for the treatment of patients with recurrent or metastatic HNSCC in addition to colorectal cancer or in combination of other cancer therapies². Cmab is a chimeric mouse-human antibody that usually binds to the extracellular domain of Epidermal Growth Factor

Receptor (EGFR). Therefore, it competes with the ligand causing inhibition of downstream EGFR signaling and also inhibition of activated STAT-3 resulting in apoptosis of cancer cells³. Cmab has affinity for epithelial cells causing toxicity due to the lack of maturation of epithelium mainly of the tongue, oesophagus and skin. Also, Cmab induces other gut toxicities including vomiting, constipation and diarrhea⁴. The side effects of cancer treatment usually appear 7 to 14 days after starting the course of treatment⁵.

*Author for correspondence

Oral mucositis (OM) was previously mentioned as a complication of anticancer therapy, affecting 40–80% of head and neck cancer patients. Relief could be obtained from topical methods but they have short term effect⁶. OM is characterized by erythema, swelling, pain, and ulceration in the lining mucosa. Pain is usually observed in patients with OM, which affects patients' ability to eat and reducing tolerability of cancer treatment⁷. Sonis (2010) explained the histopathological events following cytotoxic drug administration and explained the five-phase model of OM⁸.

The antineoplastic therapies have cytotoxic effects resulting in cell death presented as atrophy and ulceration⁸. Then it was identified that targeted anticancer drugs induce DNA and non-DNA damage (first stage) causing injury of cells. These cells produce endogenous Damage-Associated Molecular Patterns (DAMPs) that initiates inflammation by binding to specific receptors resulting in Reactive Oxygen Species (ROS) production inside the injured cells (second stage). ROS trigger the activation of transcription factors, including (NF)- κ B which is involved in mucositis (third stage)⁸.

In addition, (ROS) cause more damage to cells as the DNA starts a cascade of reactions. During these reactions, pro-inflammatory cytokines induce basal cell apoptosis but clinically the tissue appears with slight erythema. Ulceration (fourth stage) is the most significant and painful stage that appears due to bacterial colonization. Usually bacteria stimulate infiltrating macrophages to produce additional pro-inflammatory cytokines, thus producing more damage locally⁵. Healing of ulcerations (fifth phase) is associated with epithelial proliferation and reestablishment of local microbial flora⁹.

Mast cells play a vital role in the pathogenesis of mucositis. Cell appears to be round or oval in shape with round nuclei and its cytoplasm contains abundant secretory granules. According to mast cells location in the connective tissue, the nucleus can be observed or obscured by cytoplasmic granules¹⁰. Mast cell granules contain different mediators, some of them are preformed mediators such as tryptase, chymase and histamine, while others are synthesized following mast cell activation including IL-1, IL-3 and platelet activating factor¹⁰.

Abbreviations: Cetuximab (Cmab)/ damage-associated molecular patterns (DAMPs) /Grape seed extract (GSE) / Oral mucositis (OM)/ *Physalis* extract (PE) / reactive oxygen species (ROS).

In inflammation, mast cells produce factors that recruit many inflammatory cells by chemotaxis causing amplification of the inflammatory reaction and damage of tissues¹¹. The main enzymes found in mast cells granules are tryptase and chymase that activate matrix metalloproteinases. Tryptase is the main serine proteinase which promotes inflammation and tissue remodeling¹². Nogueira *et al.* (2017) pointed to the role of mast cells during the inflammation induced by irinotecan (anti-cancerous drug) in the intestine, as these cells release mediators causing macrophages activation and mucosa damage¹³.

Apoptosis is the main mechanism used by anticancer treatment. Apoptosis or programmed cell death is an organized mechanism characterized by many morphological and biochemical changes that lead to cell death. Anticancer therapies resulting in activation of apoptosis which can be initiated at the plasma membrane level upon ligation of death receptor (receptor pathway) or at the mitochondria level¹⁴. ROS generation, activation of (MAPK) pathway and inhibition of PI3K/AKT signaling pathway in tumor cells, are essential in cell survival, proliferation, and anti-apoptotic property of tumor cells. Thus Apoptosis-induced proteins are used in cancer therapy^{15,16}.

Cancer therapies activate several transduction pathways which activate transcription factors such as p53 and (NF- κ B) which finally leads to activation of pro-apoptotic or anti-apoptotic genes that determine the fate of normal tissues. All of these sequential events induce apoptosis resulting in mucositis¹⁷. Cmab drug in specific has role in inhibiting EGFR pathway, thus leads to inhibition of activated STAT-3 resulting in apoptosis of target cells and other STAT-3 mediated events such as angiogenesis³. On the other hand, cancer therapy affects the submucosal fibroblasts causing the activation of caspase-3 in fibroblasts leading to apoptotic signaling in fibroblasts and overlying epithelium. Both caspase-3 and Bax are from the main proapoptotic proteins present in the cytosol of normal cells, but they translocate to the mitochondria following

DNA damage and triggers caspase activation, resulting in apoptosis^{18,19}.

Nowadays there is a great attention to nutraceutical agents that may neutralize the harmful effect of cancer therapy²⁰. Grape Seed Extract (GSE) is a supplement which is highly marketed in the world due to its ROS modulating activity. Flavanols are phenolic components and flavonoids present in grapes are (+)-catechin, (-)-epicatechin, and proanthocyanidins²¹. Proanthocyanidins are naturally occurring phenolic compounds formed of oligomer of flavonoids. Proanthocyanidins are the most abundant phenolic compounds in grape seeds and have been reported to exert anti-inflammatory, anti-bacterial, anti-viral, anti-carcinogenic effects. Proanthocyanidins have been reported to modulate the activity of some enzymes, including phospholipase A2, COX and lipoxygenase. The anti-oxidant effect of Proanthocyanidin in the body is found to be 20 times more than vitamin C and 50 times more than vitamin E²¹. The development of severe pathologies including inflammation and cancer could be resulted from oxidative stress inside the cells. Grape polyphenols have anti-inflammatory nutritional effect by modulating the inflammatory pathways or by reducing ROS levels. Thus, they are more effective compared to synthetic anti-inflammatory drugs²². They also have an immune-modulatory role in inflammatory conditions that exert an overproduction of NO and prostaglandin E2²². Moreover, *in vivo* research done by Procházková *et al.* (2011) states that flavonoids have indirect role as antioxidants by up-regulating antioxidant defense system and increasing uric acid concentration in the plasma²³. GSE was reported previously to be able to reduce mucosal injury in rat models of intestinal mucositis²⁴. Consumption of polyphenols produces very few side effects and no significant toxicity was documented in the literature up to 1 gm/kg/d. Procyanidins are stable in an acid-based environment (stomach) but flavonoids digestion are highly affected by milk, because procyanidins in GSE with milk protein related to higher degree of polymerization²⁵.

A superfruit is a newly introduced term in the market and the high popularity of these fruits depend heavily on scientific results of research. The tropical

plant *Physalis peruviana* is a member of the Solanaceae family. This fruit is cultivated in many areas including Egypt and South America. *Physalis peruviana* (PP) is known local markets in Egypt as Harankash and known in other countries as Cape gooseberry²⁶. The fruit is sweet, tangy, with ovoid shape and has a diameter of 1.25–2.50 cm, containing around 100–200 small seeds inside. This fruit has a high content of β -carotene, vitamins (A, B, C and E), minerals (such as iron), withanolides C and bioflavonoids²⁷. Polyphenols and carotenoids are important antioxidant components in Cape gooseberry. These phytochemicals can reduce inflammation via inhibiting prostaglandin production, NF κ B activity and free radical scavenging abilities as well as by increasing cytokine production²⁸. Methanol, ethanol and hot aqueous extracts of PP were also evaluated for anti-oxidant activities but the highest anti-oxidant activity was observed in 95% ethanol extract and in addition, this extract demonstrated a strong superoxide anion scavenging activity. Mohammed and Ibraheem (2017) concluded from their study that the antioxidant and free-radical scavenging activities of PP exceeded (vitamin E) and vitamin C, due to high flavonoid contents which is important anti-oxidant chemical component of the plant²⁹. In addition, Chang *et al.* (2016) explained in their study that PP down regulate the activities of aberrantly-active NF- κ B and STAT3, two key redox-regulated transcription factors that control cellular and disease processes. Also they reported that *Physalis* contain compounds that can block either one or both of these transcriptions factors, and inhibit nitric oxide production suggesting that it can be used as anti-inflammatory agent²⁰. In addition, Ahmed (2014) revealed that the pretreatment of PP protected the kidney against toxicity produced by cisplatin (anti-cancer drug) by preventing the drug (cisplatin) induced decrease of renal antioxidant defense system³⁰. Kasali *et al.* (2013) noticed that 100 mg/kg dose of PP is sufficient and safe with no toxicity but, toxicity was recorded at a dose higher (800 mg/kg) including hesitation, hair rustling, anuria and finally death³¹. The aim of the present study is to compare between the effect of grape seed extract and *Physalis* extract on the inflammation of tongue mucosa caused by Cetuximab drug in experimental rats.

2. Materials and Methods

Cetuximab (Cmab) was purchased from Merck Company. Grape Seed Extract (GSE) pure powder was purchased from Bulk Supplements Company. *Physalis peruviana* was purchased from a local market in Egypt. All the steps of the extract preparation were done in the National Research Center in Cairo. Monoclonal anti-mast cell tryptase antibody was used to detect the presence of the mast cells in mucositis induced by Cmab drug. The monoclonal anti-bax antibody was used to assess apoptosis associated with mucositis. Both antibodies were purchased from Biospes Company.

2.1 Preparation of Physalis Extract

The fruits of *Physalis peruviana* were purchased from the local farmer market during the spring season and were carefully selected according to the grade of ripeness measured by fruit color (brilliant gold). Fruits were dehusked, cut in halves, dried in solar ovens on stainless steel mesh trays at temperature $\leq 45^{\circ}\text{C}$ and finally the dried fruits were grinded in to powder. Thirty kilograms fresh fruits yielded ≈ 4.2 (14%) dry powder. The powder was exhaustively extracted with 85% methanol (Methanol GR for analysis, Merck). The methanol extracts were filtered, evaporated under vacuum at 35°C using Büchi Rotatory evaporator R-114 and stored at -20°C . The yield was (1150g \approx 3.83

% of the original fresh fruit weight). The extraction and drying procedures were done cautiously to guard against denaturation³².

2.2 Sample Size

The total sample size was calculated for 'fixed effects single factor design', The alpha level is $\alpha=0.05$ and effect size $f=0.8$. The power is 0.95 using G Power and significance level is 0.05. The sample size for the experimental design was calculated to be a total of sixty rats divided among the six groups into ten rats for each group.

2.3 Housing and Animal Grouping

The experimental rats were obtained and housed in the animal house of the National Research Center in Cairo, Egypt according to the recommendations and approval of Institutional Animal Care and Use Committee, Cairo University (IACUC) (Approval number CU/III/S/48/17). Rats were divided into six groups as mentioned in Table 1. Rats were housed in stainless-steel cages, 5 rats per cage. All rats were maintained on basic diet of regular rat chow and distilled water.

2.4 Euthanasia

Euthanasia was done for all experimental groups on the 16th day from the start of Cmab administration by an overdose of anesthetic solution (1ml/100gm)³³.

Table 1. Study design and animals grouping

	Group I	Group II	Group III. a	Group III. b	Group IV. a	Group IV. b
No. of rats	10	10	10	10	10	10
Cmab dose and route	no	0.25 mg/ i.p injection	0.25 mg/ i.p injection	0.25 mg/ i.p injection	0.25 mg/i.p injection	0.25 mg/i.p injection
GSE dose and route	no	no	20 mg/day oral administration in parallel course with Cmab drug	20 mg/day oral administration one week ahead to Cmab drug	no	no
PP dose and route	no	no	no	no	20 mg/day oral administration in parallel course with Cmab drug	20 mg/day oral administration one week ahead to Cmab drug

2.5 Tissue Preparation

Each tongue was dissected and fixed in 10% buffered formalin for 24 hours, then dehydrated in ascending grades of ethyl alcohol, cleared in xylene and embedded in paraffin. Some sections were cut into 4 microns for staining by hematoxylin and eosin. Other sections were cut into 3 micron thick sections and placed on positively charged (Opti-Plus) slides for immunostaining by mast cell tryptase and other slides by bax immune-stain. Immunostaining for mast cell tryptase and bax sections were performed using Ventana Benchmark autostainer (USA).

2.6 Assessment of Histological Sections

It was performed by light microscope and Computer image analyzer to examine all the stained sections using the software Leica Qwin 500 (Germany), the number of filiform papillae and mast cells stained with mast cell tryptase were counted in each group with a measuring frame of $24790 \mu\text{m}^2$, where three fields were measured for each slide using a magnification (x100). The area percent of bax was measured in a measuring frame of $61934 \mu\text{m}^2$, where three fields were measured for one slide of each rat using a magnification (x400). Areas of the most intense staining were selected then

the computer system converted the picture into a green binary color that could be calculated.

2.7 Statistical Analysis

Data obtained was presented as mean and standard deviation (\pm SD) values for each group. One Way Analysis of Variance (ANOVA) test was used for comparison between the studied groups followed by Tukey's Post-Hoc Test for pair wise comparison between the means when ANOVA test is significant. The significant level was set at P value ≤ 0.05 .

3. Results

3.1 Histological Results

The differences between the filiform papillae and muscle fibers in the underlying tongue mucosa in hematoxylin and eosin stained sections are shown in figure 1. It was obvious that group IV b, the rats taking PP before starting Cmap drug were almost look like group I of normal rats. Groups taking GSE showed more destructed papillae and muscle atrophy than group of PP but finally the worst results were noted in group II taking Cmap drug only.

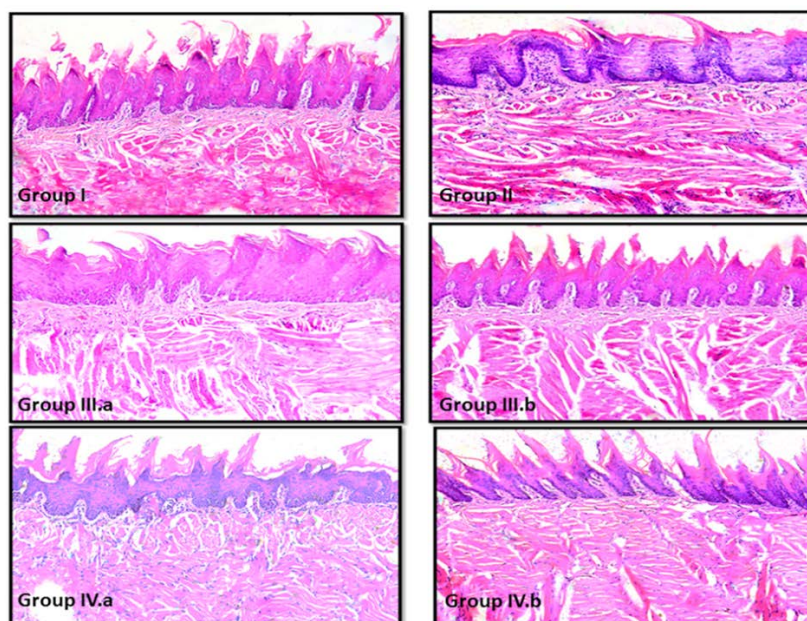


Figure 1. The photomicrograph showing the differences between the appearances of filiform papillae in all experimental groups (x100).

In mast cell tryptase stained sections, the differences in mast cell tryptase immune-expression are shown in figure 2. Greatest number of mast cells was observed in group II taking Cmab drug only followed by Groups III b and a taking GSE and Cmab drug. The least number of mast cells was recorded in groups taking PP with minimal number as shown in Group IV b taking PP one week ahead, which was almost similar to group I of normal rats.

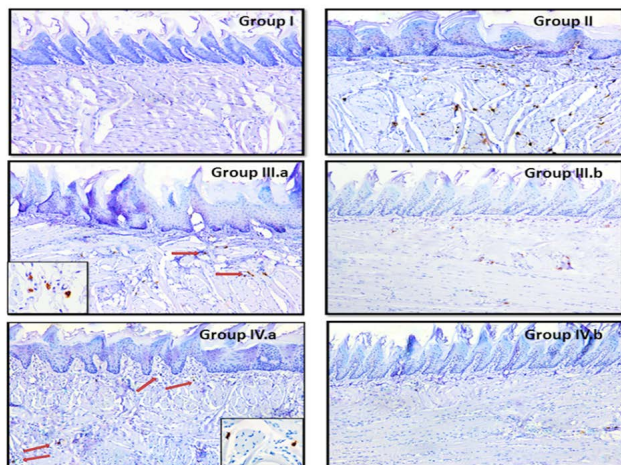


Figure 2. The photomicrograph showing the differences between mast cell tryptase immune-expression in different sections of experimental groups (x100).

In bax immune-stained sections, the variation in bax immune-expression was detected between the experimental groups and shown in Figure 3. The largest area of immune expression was seen in Group II taking Cmab drug only but the groups of GSE (Groups III a and b) and PP (Groups IV a and b) showed lower expression than Group II but higher than normal control Group I. All the mentioned findings are summarized in Table 2.

3.2 Statistical Analysis

3.2.1 The Mean Number of Filiform papillae in Tongue Mucosa of all Groups. (ANOVA test)

ANOVA test revealed that the difference between the groups was statistically significant ($P < 0.0001$). Tukey's post hoc test for pairwise comparison revealed no significant difference between Groups (III b and IV a) (Table 3, Figure 4).

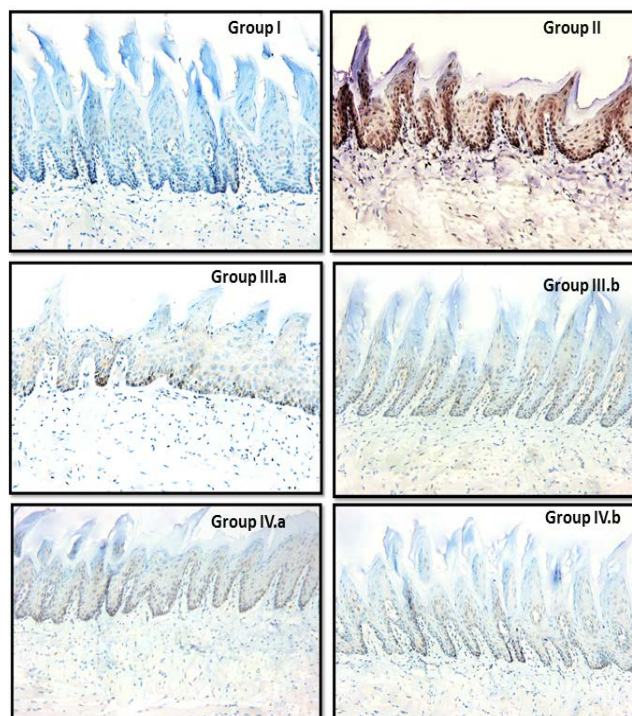


Figure 3. The photomicrograph showing the differences between bax immune-expression in the epithelium of the tongue mucosa in different sections of the experimental groups (x200).

3.2.2 The Mean Number of Mast Cells in all Experimental Groups Summarized in the Following Table. (ANOVA test)

ANOVA test revealed that the difference between the groups was statistically significant ($P < 0.0001$). Tukey's post hoc test for pairwise comparison revealed no significant difference between Groups (IIIa and IVa) (IIIb and IVb) (Table 4, Figure 5).

3.2.3 The Mean Values of Area Percent of Bax Immune-expression in Epithelium of Tongue Mucosa in all Experimental Groups of Rats Summarized in the Following Table. (ANOVA test)

ANOVA test revealed that the difference between the groups was statistically significant ($P < 0.0001$). ANOVA test revealed that the difference between the groups was statistically significant ($P < 0.0001$). Tukey's post hoc test for pairwise comparison revealed no significant difference between Groups (IIIa and IVa) and (IVa and IVb) (Table 5, Figure 6).

Table 2. Summary of the results in bax immune-stained sections

finding	Group I	Group II	Group III a	Group III b	Group IV a	Group IV b
Tongue papillae	Well-formed on the same horizontal level.	Loss in large areas and atrophy of the remaining papillae.	Loss of some and atrophy of most of the remaining papillae.	Slight atrophy of some papillae without any loss.	Loss of few papillae and atrophy of the remaining papillae. slight separation of muscle fibers slight separation of muscle fibers	Slight atrophy of few papillae while the remaining papillae had normal appearance. slight atrophy of few filliform papillae. slight atrophy of few filliform papillae. Slight separation of muscle fibers Slight separation of muscle fibers
Muscle fibers	No atrophy	Severe atrophy and separation	Atrophy and separation	Atrophy and separation	Slight separation slight separation of muscle fibers	Slight separation
Mast cell tryptase immune expression	Almost Absence of immune-expression	Strong in numerous cells	Strong in some cells	Strong in few number of mast cells	Strong in few number of mast cells	Strong in very small number of mast cells
Bax immune expression in the epithelium	Very faint cytoplasmic expression in some supra basal cells and nuclear expression in some basal cells.	Strong cytoplasmic expression in almost the entire epithelium and nuclear expression in basal cells	Moderate cytoplasmic expression in large areas. Strong nuclear expression in some basal cells	Week cytoplasmic in small focal areas and nuclear expression in some basal	Moderate cytoplasmic expression in large areas and Strong Nuclear expression in basal cells.	Weak cytoplasmic expression in some small areas and nuclear expression in basal cells.

Table 3. Comparison between the mean numbers of filiform papillae in all groups

	Group I	Group II	Group III		Group IV	
			a	b	a	b
Mean	15.5 ^a	2.2 ^b	7.4 ^c	10.5 ^d	9.6 ^d	12.9 ^e
SD	1.02	0.75	1.11	1.28	1.11	1.14
Std error	0.34	0.25	0.37	0.43	0.37	0.38
Min	14	1	6	8	8	11
Max	17	3	9	12	12	15
F value	181.699					
P value	0.000*					

*Significant at p<0.05

Means with different superscript letters are significantly different (Tukey's post hoc test).

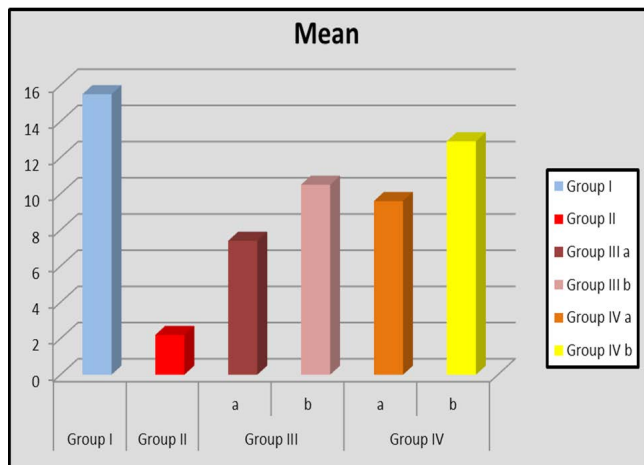


Figure 4. The Column chart showing mean number of filiform papillae in all experimental groups.

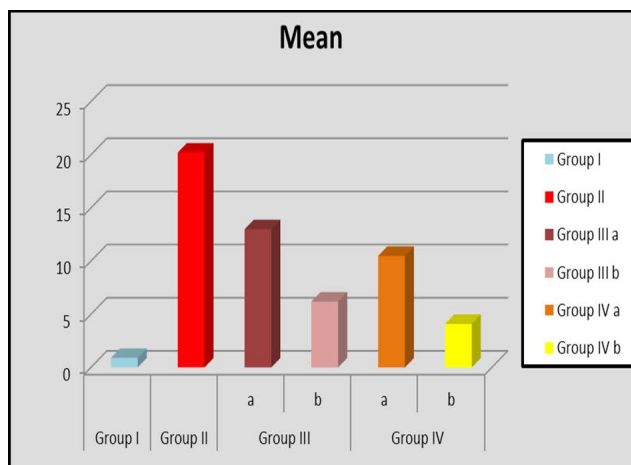


Figure 5. The column chart showing mean number of mast cells in all experimental groups

Table 4. Comparison between mean numbers of mast cells in all the groups

	Group I	Group II	Group III		Group IV	
			a	b	a	b
Mean	0.9 ^d	20.22 ^a	13 ^b	6.2 ^c	10.5 ^b	4.1 ^c
SD	1.04	4.049	4.47	2.95	3.87	2.07
Std error	0.34	1.43	1.49	0.98	1.29	0.69
Min	0	15	7	0	5	1
Max	3	28	20	12	18	8
F value	44.284					
P value	0.000*					

*Significant at p<0.05

Means with different superscript letters are significantly different. (Tukey's post hoc test)

Table 5. Mean area percent of bax immune expression in all groups. (ANOVA test)

Comparison between mean area percent of bax immune expression in all the groups						
	Group I	Group II	Group III		Group IV	
			a	b	a	b
mean	1.497 ^a	17.389 ^b	4.467 ^c	3.455 ^d	6.303 ^{c&e}	6.153 ^e
St.dv	0.561	2.321	0.628	0.642	2.615	0.725
Min	0.783	13.302	3.817	2.678	3.577	5.315
Max	2.474	20.336	5.442	4.113	9.819	7.435
F-value	67.972					
P-value	<0.0001*					

*Significant at p<0.05

Means with different superscript letters are significant different (Tukey's post hoc test).

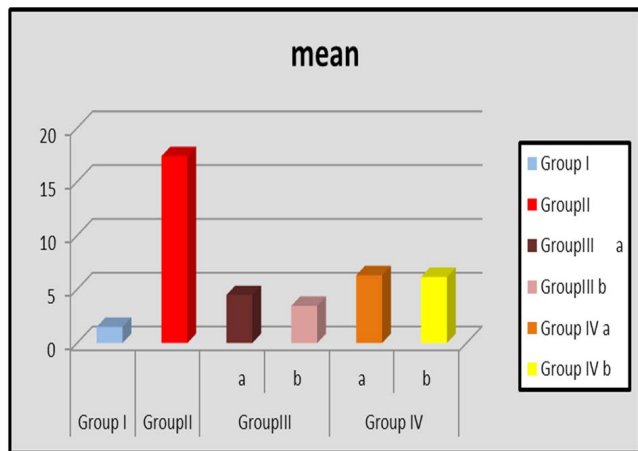


Figure 6. Column chart showing mean area percent of bax immunoreexpression in all experimental groups.

4. Discussion

Cancer patients do not die because of cancer itself but also from complications associated with the cancer treatment. Cmab has high affinity towards EGFR and it depends in its action on apoptosis induction which could damage the mucosa causing mucositis⁴. It causes DNA and non DNA damage in the cells, leading to production of DAMPS molecules thus increasing the level of ROS causing inflammation⁵. Moreover, the up regulation of the production of DAMPS molecules leads to activation and degranulation of mast cells which in turn induces more inflammation⁴. Cmab is an anti-EGFR monoclonal antibody that induces cell cycle arrest and apoptosis resulting in skin toxicity and mucositis³⁴. The administration of Cmab is followed by acute damage phase, formed of inflammation and epithelial apoptosis. Then, self-healing stage that ends with restoring normal epithelium occurs⁵. In the present study, bax was used to assess apoptosis induced by Cmab drug while mast cell tryptase was used as an indicator of the inflammatory reactions. The nutraceutical used in this study were GSE and PP, GSE was commercially available as ready-made supplement while PP needed to be prepared from fresh golden berries collected from local market at the ripe stage as per the reports of Valdenegro *et al.* (2012) to ensure its high nutritional value as the storage for long periods deteriorate its properties³⁵.

In the current experiment rats were selected because of their ability to breed quickly³⁶. Cmab drug was administrated by direct infusion into the peritoneal cavity as it is not stable in the acidic medium of GIT, while the GSE and PP are stable in acid base environment and so could be given orally²⁵. Euthanasia of rats of all experimental groups was done on 16th day from starting Cmab drug administration for studying the recent histological changes in rats after completing the treatment course. As mentioned by Pouloupoulo *et al.* (2017), the toxic effects of chemotherapy on mucosa begin shortly starting the therapy and eventual resolution occurs within two to four weeks³⁷. We studied the loss and atrophy of filiform papillae as they occurred faster and earlier than other types of papillae due to their high metabolic activity.

In Group I (normal rats), tongue mucosa was entirely covered by well-formed filiform papillae on the same horizontal level and normally, mast cells are hardly detected in tongue mucosa. In contrast, Group II (rats were given Cmab only) showed severe loss and atrophy of filiform papillae with the highest number of mast cells indicating severe inflammatory response due to toxicity induced by the Cmab drug in comparison to other groups. In Groups IIIa (rats were given GSE simultaneously with Cmab drug) showed better reduction in destructed tongue papillae and reduction in number of mast cells compared to Cmab group (Group II) indicating GSE can reduce mucositis. This is in accordance with Cheah *et al.* (2013) findings that there is a reduction in intestinal damage induced by chemotherapeutic agent in animals receiving GSE²⁴. In addition, Group IIIb (rats were given GSE one week as prophylaxis before Cmab drug) had better results in inflammation reduction than Group III a, indicating that the duration and time of administration of GSE intake are important factors in resisting the inflammatory process. Furthermore, Group IV a (rats were given PP simultaneously with Cmab drug) showed better reduction in number of mast cells and destructed tongue papillae revealing decrease in mucositis than Group III a (rats were given GSE simultaneously with Cmab), but best results obtained in Group IV b (rats were given PP one week ahead to Cmab drug as prophylaxis) as the tongue mucosae of the rats in this group almost looked like normal control rats.

Cmab drug induces apoptosis of normal cells aggravating oral mucositis which in turn impairs oral functions. This occurs via NF- κ B activation that leads to increase the expression of pro-apoptotic genes such as bax resulting in mucositis³⁸. In the current experiment a stronger immune-expression of bax was observed in Group II (taking Cmab only) compared to other groups indicating high apoptotic rate in the mucositis induced by this therapeutic agent.

Bax is proapoptotic protein found in the cytoplasm of cells, but it transfers to the mitochondria following DNA damage and triggers caspase activation, resulting in apoptosis. This could explain the cytoplasmic immune-expression of bax in the epithelium observed in the current experiment¹⁷. Regarding the assessment of bax among the experimental groups, a significant difference in mean area percent of bax was detected between Group II (taking Cmab only) and other groups (taking extracts with Cmab drug) proves that both GSE and PP extracts have valuable effects in reducing apoptosis induced by Cmab drug. The results are in coincidence with Porcelli *et al.* (2017) report that the drastic reduction of the pro-apoptotic proteins when GSE was added to the treatment of groups in case of chemotherapy induced mucositis³⁹.

Interestingly, no significant difference in mean area percent of bax immune-expression between GSE and PP groups suggesting that anti-apoptotic effect of both extracts is closely similar regarding the given dose. The least mean area percent of bax recorded in group I as they are normal rats with normal low rate of apoptosis found in the cells. The tongue mucosa PP groups looked almost like that of normal group suggesting that PP is more powerful neutralizer for the toxicity induced by Cmab drug than GSE.

5. Conclusion

Administration of GSE or PP before starting the Cmab treatment had more powerful anti-inflammatory effect and offered more protection against the drug toxicity. Our findings proved that PP provides better reduction in mucositis induced by Cmab drug than GSE. Administration of any of these extracts as prophylaxis before starting the cancer therapy will result in more reduction in the toxicity induced by cancer therapy.

6. Acknowledgement

I would like to thank all the staff members in Oral and Maxillofacial Pathology Department, Faculty of Dentistry, Cairo University, Egypt. I shouldn't miss the chance to thank all the staff of pharmacognacy Department in National Research Center in Cairo for their great help to carry out this work.

7. Funding

This research did not receive any specific grant from funding agencies in the public, commercial, or not-for-profit sectors.

8. Authors Contribution

Heba Ahmed Saleh: Conducted the experiment and wrote the manuscript/ the corresponding author

Manar Abdul Aziz: She created the idea of the research and also revised the writing of this work

Mona Wali: She performed the final supervision for every step in this work

9. Conflict of Interest

None declared

10. References

1. Nguyen A, Hoang V, Laquer V, Kelly KM. Angiogenesis in cutaneous disease: part I. *Journal of the American Academy of Dermatology*. 2009 Dec 1; 61(6):921–42. <https://doi.org/10.1016/j.jaad.2009.05.052>. PMID:19925924
2. Santuray RT, Johnson DE, Grandis JR. New therapies in head and neck cancer. *Trends in Cancer*. 2018 May 1; 4(5):385–96. <https://doi.org/10.1016/j.trecan.2018.03.006>. PMID:29709262. PMCID:PMC6226306
3. Bonner JA, Trummell HQ, Bonner AB, Willey CD, Bredel M, Yang ES. Enhancement of cetuximab-induced radiosensitization by JAK-1 inhibition. *BMC Cancer*. 2015 Oct 12; 15(1):673–775. <https://doi.org/10.1186/s12885-015-1679-x>. PMID:26458879. PMCID:PMC4603644
4. Keefe DM, Gibson RJ. Mucosal injury from targeted anti-cancer therapy. *Supportive Care in Cancer*. 2007 May 1; 15(5):483–90. <https://doi.org/10.1007/s00520-006-0181-z>. PMID:17103195
5. Al-Ansari S, Zechar JA, Barasch A, de Lange J, Rozema FR, Raber-Durlacher JE. Oral mucositis induced by anticancer

- therapies. *Current Oral Health Reports*. 2015 Dec 1; 2(4):202–11. <https://doi.org/10.1007/s40496-015-0069-4>. PMID:26523246. PMCid:PMC4623065
6. da Cruz Campos MI, Neiva Campos C, Monteiro Aarestrup F, Aarestrup V, Julião B. Oral mucositis in cancer treatment: Natural history, prevention and treatment. *Molecular and Clinical Oncology*. 2014 May 1; 2(3):337–40. <https://doi.org/10.3892/mco.2014.253>. PMID:24772297. PMCid:PMC3999143
 7. Al-Dasooqi N, Sonis ST, Bowen JM, Bateman E, Blijlevens N, Gibson RJ, et al. Emerging evidence on the pathobiology of mucositis. *Supportive Care in Cancer*. 2013 Jul 1; 21(7):2075–83. <https://doi.org/10.1007/s00520-013-1810-y>. PMID:23604521
 8. Sonis ST. New thoughts on the initiation of mucositis. *Oral Diseases*. 2010 Oct; 16(7):597–600. <https://doi.org/10.1111/j.1601-0825.2010.01681.x>. PMID:20846150
 9. Al-Dasooqi N, Gibson RJ, Bowen JM, Logan RM, Stringer AM, Keefe DM. Matrix metalloproteinases are possible mediators for the development of alimentary tract mucositis in the dark agouti rat. *Experimental Biology and Medicine*. 2010 Oct; 235(10):1244–56. <https://doi.org/10.1258/ebm.2010.010082>. PMID:20682600
 10. Gaje PN, AmaliaCeausu R, Jitriu A, Stratul SI, Rusu LC, Popovici RA, et al. Mast cells: Key players in the shadow in oral inflammation and in squamous cell carcinoma of the oral cavity. *BioMed Research International*. 2016; 2016. <https://doi.org/10.1155/2016/9235080>. PMID:27847826. PMCid:PMC5101369
 11. Dražić R, Sopta J, Minić AJ. Mast cells in periapical lesions: potential role in their pathogenesis. *Journal of Oral Pathology & Medicine*. 2010 Mar; 39(3):257–62. <https://doi.org/10.1111/j.1600-0714.2009.00870.x>. PMID:20359310
 12. Kabashima K, Nakashima C, Nonomura Y, Otsuka A, Cardamone C, Parente R, et al. Biomarkers for evaluation of mast cell and basophil activation. *Immunological Reviews*. 2018 Mar; 282(1):114–20. <https://doi.org/10.1111/imr.12639>. PMID:29431209
 13. Nogueira LT, Costa DV, Gomes AS, Martins CS, Silva AM, Coelho-Aguiar JM, et al. The involvement of mast cells in the irinotecan-induced enteric neurons loss and reactive gliosis. *Journal of Neuroinflammation*. 2017 Dec; 14(1):79. <https://doi.org/10.1186/s12974-017-0854-1>. PMID:28388962. PMCid:PMC5384042
 14. Pfeffer CM, Singh AT. Apoptosis: A target for anticancer therapy. *International Journal of Molecular Sciences*. 2018 Feb; 19(2):448. <https://doi.org/10.3390/ijms19020448>. PMID:29393886. PMCid:PMC5855670
 15. Hamad Í, Erol-Dayi Ö, Pekmez M, Önay-Uçar E, Arda N. Antioxidant and cytotoxic activities of *Aphanes arvensis* extracts. *Plant Foods for Human Nutrition*. 2010 Mar 1; 65(1):44–9. <https://doi.org/10.1007/s11130-009-0151-y>. PMID:20108047
 16. Çakir Ö, Pekmez M, Çepni E, Candar B, Fidan K. Evaluation of biological activities of *Physalis peruviana* ethanol extracts and expression of Bcl-2 genes in HeLa cells. *Food Science and Technology*. 2014 Jun; 34(2):422–30. <https://doi.org/10.1590/fst.2014.0060>
 17. Talwar S, House R, Sundaramurthy S, Balasubramanian S, Yu H, Palanisamy V. Inhibition of caspases protects mice from radiation-induced oral mucositis and abolishes the cleavage of RNA-binding protein HuR. *Journal of Biological Chemistry*. 2014 Feb 7; 289(6):3487–500. <https://doi.org/10.1074/jbc.M113.504951>. PMID:24362034. PMCid:PMC3916550
 18. Dewson G, Kluck RM. Mechanisms by which Bak and Bax permeabilise mitochondria during apoptosis. *Journal of Cell Science*. 2009 Aug 15; 122(16):2801–8. <https://doi.org/10.1242/jcs.038166>. PMID:19795525. PMCid:PMC2736138
 19. Tait SW, Green DR. Mitochondria and cell death: Outer membrane permeabilization and beyond. *Nature Reviews Molecular Cell Biology*. 2010 Sep; 11(9):621–32. <https://doi.org/10.1038/nrm2952>. PMID:20683470
 20. Chang LC, Sang-ngern M, Pezzuto JM, Ma C. The Daniel K. Inouye College of Pharmacy Scripts: Poha berry (*Physalis peruviana*) with potential anti-inflammatory and cancer prevention activities. *Hawai'i Journal of Medicine and Public Health*. 2016 Nov; 75(11):353.
 21. Yen CY, Hou MF, Yang ZW, Tang JY, Li KT, Huang HW, et al. Concentration effects of grape seed extracts in anti-oral cancer cells involving differential apoptosis, oxidative stress, and DNA damage. *BMC Complementary and Alternative Medicine*. 2015 Dec; 15(1):1–9. <https://doi.org/10.1186/s12906-015-0621-8>. PMID:25880412. PMCid:PMC4393634
 22. Georgiev V, Ananga A, Tsoлова V. Recent advances and uses of grape flavonoids as nutraceuticals. *Nutrients*. 2014 Jan; 6(1):391–415. <https://doi.org/10.3390/nu6010391>. PMID:24451310. PMCid:PMC3916869
 23. Procházková D, Boušová I, Wilhelmová N. Antioxidant and prooxidant properties of flavonoids. *Fitoterapia*. 2011 Jun 1; 82(4):513–23. <https://doi.org/10.1016/j.fitote.2011.01.018>. PMID:21277359
 24. Cheah KY, Bastian SE, Acott TM, Abimosleh SM, Lynn KA, Howarth GS. Grape seed extract reduces the severity of selected disease markers in the proximal colon of dextran sulphate sodium-induced colitis in rats. *Digestive Diseases and Sciences*. 2013 Apr 1; 58(4):970–7. <https://doi.org/10.1007/s10620-012-2464-1>. PMID:23143736
 25. Cilla A, González-Sarriás A, Tomás-Barberán FA, Espín JC, Barberá R. Availability of polyphenols in fruit beverages subjected to in vitro gastrointestinal digestion and their effects on proliferation, cell-

- cycle and apoptosis in human colon cancer Caco-2 cells. *Food Chemistry*. 2009 Jun 1; 114(3):813–20. <https://doi.org/10.1016/j.foodchem.2008.10.019>
26. Nawirska-Olszańska A, Stepień B, Biesiada A, Kolniak-Ostek J, Oziembłowski M. Rheological, chemical and physical characteristics of golden berry (*Physalis peruviana* L.) after convective and microwave drying. *Foods*. 2017 Aug; 6(8):60. <https://doi.org/10.3390/foods6080060>. PMID:28758918. PMCID:PMC5575635
 27. Puente LA, Pinto-Muñoz CA, Castro ES, Cortés M. *Physalis peruviana* Linnaeus, the multiple properties of a highly functional fruit: A review. *Food Research International*. 2011 Aug 1; 44(7):1733–40. <https://doi.org/10.1016/j.foodres.2010.09.034>
 28. Zhang YJ, Gan RY, Li S, Zhou Y, Li AN, Xu DP, Li HB. Antioxidant phytochemicals for the prevention and treatment of chronic diseases. *Molecules*. 2015 Dec; 20(12):21138–56. <https://doi.org/10.3390/molecules201219753>. PMID:26633317. PMCID:PMC6331972
 29. Mohammed ZH, Ibraheem RM. Anti-oxidant activity of methanol extracts of *Arum maculatum* L. and *Physalis peruviana* L. *Plants*. Ibn AL-Haitham Journal For Pure and Applied Science. 2017 Mar 13; 28(2):1–7.
 30. Ahmed LA. Renoprotective effect of Egyptian cape gooseberry fruit (*Physalis peruviana* L.) against acute renal injury in rats. *The Scientific World Journal*. 2014; 2014. <https://doi.org/10.1155/2014/273870>. PMID:24757415. PMCID:PMC3976858
 31. Kasali FM, Kadima JN, Mpiana PT, Tshibangu DS. Assessment of antidiabetic activity and acute toxicity of leaf extracts from *Physalis peruviana* L. in guinea-pig. *Asian Pacific Journal of Tropical Biomedicine*. 2013 Nov 1; 3(11):841–6. [https://doi.org/10.1016/S2221-1691\(13\)60166-5](https://doi.org/10.1016/S2221-1691(13)60166-5)
 32. Sasidharan S, Chen Y, Saravanan D, Sundram KM, Latha LY. Extraction, isolation and characterization of bioactive compounds from plants' extracts. *African Journal of Traditional, Complementary and Alternative Medicines*. 2011; 8(1). <https://doi.org/10.4314/ajtcam.v8i1.60483>
 33. Underwood W, Anthony R, Cartner S, Corey D, Grandin T, Greenacre C, et al. AVMA guidelines for the euthanasia of animals: 2013 edition. Schaumburg, IL: American Veterinary Medical Association. (Schaumburg, IL: JAVMA-J AM VET MED A, 2013 accessed on 20 September 2019)
 34. Dai W, Li Y, Zhou Q, Xu Z, Sun C, Tan X, Lu L. Cetuximab inhibits oral squamous cell carcinoma invasion and metastasis via degradation of epidermal growth factor receptor. *Journal of Oral Pathology and Medicine*. 2014 Apr; 43(4):250–7. <https://doi.org/10.1111/jop.12116>. PMID:24020947
 35. Valdenegro M, Fuentes L, Herrera R, Moya-León MA. Changes in antioxidant capacity during development and ripening of goldenberry (*Physalis peruviana* L.) fruit and in response to 1-methylcyclopropene treatment. *Postharvest Biology and Technology*. 2012 May 1; 67:110–7.
 36. Sengupta P. A scientific review of age determination for a laboratory rat: How old is it in comparison with human age. *BioMed Research International*. 2011; 2(2):81–9. <https://doi.org/10.1016/j.postharvbio.2011.12.021>
 37. Pouloupoulos A, Papadopoulos P, Andreadis D. Chemotherapy: Oral side effects and dental interventions. A review of the literature. *Stomatological Disease and Science*. 2017; 2573-0002. <https://doi.org/10.20517/2573-0002.2017.03>
 38. Wu X, Chen P, Sonis ST, Lingen MW, Berger A, Toback FG. A novel peptide to treat oral mucositis blocks endothelial and epithelial cell apoptosis. *International Journal of Radiation Oncology* Biology* Physics*. 2012 Jul 1; 83(3):e409–15. <https://doi.org/10.1016/j.ijrobp.2012.01.006>. PMID:22420966. PMCID:PMC3361587
 39. Porcelli L, Iacobazzi RM, Quatralo AE, Bergamini C, Denora N, Crupi P, et al. Grape seed extracts modify the outcome of oxaliplatin in colon cancer cells by interfering with cellular mechanisms of drug cytotoxicity. *Oncotarget*. 2017 Aug 1; 8(31):50845. <https://doi.org/10.18632/oncotarget.15139>. PMID:28881609. PMCID:PMC5584210