



Anti-Hepatotoxic Effect of *Glinus lotoides* Linn. on Rifampicin Induced Liver Impairment in Albino Rats

K. Sudha Rameshwari* and P. Arockia Selvi

Department of Biochemistry, V. V. Vanniaperumal College for Women, Virudhunagar - 626001, Tamil Nadu, India; sudharameshwari@vvvcollege.org

Abstract

Liver ailment is one of the severe health issues all over the sphere. Hepatic damage or failure due to consumption and breathing of hepatotoxin is increasing worldwide. Rifampicin high dosage can cause severe injury to the liver. Today publics wish herbal drugs due to its high efficiency and absence of side effects. Herbal medicines are available for each and every disorder ranging from diabetes to rejuvenators. These facts promoted us to select a medicinal plant *Glinus lotoides* for the present study which is known as 'Siruserupadai' in Tamil. Amid the later ponder, ethanolic extricate was chosen for the anti-hepatotoxicity action; it has maximum numbers of phytoconstituents (Glycosides, saponins, proteins, alkaloids, and flavanoids). Five groups of animals were taken for the test named as control, rifampicin treated group, Silymarin treated group (10 mg/Kg), Ethanolic Extract of *Glinus lotoides* Linn. (EEGL) treated group (200 mg/Kg), EEGL treated group 400 mg/kg. Rifampicin effectively and particularly ties to RNA polymerase; it represses the amalgamation of all shapes of RNA. It induces fatty liver and finally cirrhosis which is excited by increment the action of serum biological catalysts like SGPT, SGOT and alkaline phosphatase. The hepatoprotective activities was appeared by bringing down the serum biochemical parameters (enzymes and bilirubin) within the rifampicin inebriated rats pre-treated with ethanolic extricate at 200 and 400 mg/kg. The prophylactic impact is reasonably comparable to that of Silymarin, suggesting the EEGL can be potential source of hepatoprotectives.

Keywords: *Glinus lotoides* Linn., Hepatoprotective Effect, Phytochemical Analysis, Rifampicin, Silymarin, Wister Albino Rats

1. Introduction

Recent years, indeed in ranges where latest medications are accessible, the intrigued-on home grown medications and after that use has been expanding rapidly¹. Hepatic failure remains one of the serious health problems throughout the world. Rifampicin overdose can cause severe injury to the hepatocyte. Medicinal plants show an important role in the well-being and its efficiency and not any side effects. People prefer herbal medicines nowadays. Herbal medicines are available for each and every disorder ranging from diabetes to rejuvenators. These facts promoted us to select a medicinal plant *Glinus lotoides* Linn. for the

present study which is known as 'siruserupadai' in Tamil. *Glinus lotoides* Linn. is a smelling aromatic herb belonging to the family Molluginaceae. *Glinus lotoides* are customarily utilized as anthelmintic to avoid tapeworm contamination. In Punjab locale this plant is utilized to remedy the loose bowels, connected to tingles and skin maladies by conventional local practitioners². It is being used for cough, tuberculosis, Hickup, thirsty, Asthma, AIDS, Anti-spasmodic³, Anti-Ulcerogenic⁴, anti-cancer activity⁵ and wound healing activity⁶ activity. From the existing literature and information from 'Napralet', we have selected hepatoprotective activity screening for the present work which could not be attempted by any research earlier.

*Author for correspondence

2. Materials and Methods

2.1 Plant Gathering and Extraction

The *Glinus lotoides* Linn. hexane and ethanol extracts were prepared for the study in the ratio of 1:10 (1g of dried plant powder with 10 ml of solvent). Hexane and Ethanol extraction was done by Soxhlet apparatus. Extraction was done up to colourless solvent. Solvent was collected in brown bottle for use. Solvent extract of *Glinus lotoides* was collected from round bottom flask and air dried. These samples were taken to carry out the phytochemical studies.

2.2 Qualitative Analysis of Phytochemical Constituents

The extracts are subjected to phytochemical studies for the identification of various plant constituents such as proteins, alkaloids, tannins, flavonoids, sterols, glycosides, saponins, carbohydrates⁷.

2.3 Pharmacological Examination

Wister strain albino rats (125-175 g) were utilized for the current study. These animals were fed with standard pelleted diet supplied by Kamathenu agencies, Bangalore and drinking water. These animals were obtained from an inbreed colony animals which was being maintained locally at Sankaralingam Bhuvaneshwari College of Pharmacy (SBCP) animal house at Annaikuttam, Sivakasi, Tamilnadu, India. The rats were divided into five groups with six animals in an individual group. Group I – normal control -1ml/Kg saline, Group II – rifampicin treated group, Group III – Silymarin treated -100mg/Kg-single dose orally, Group IV - Ethanolic extract of *Glinus lotoides* - 200mg/Kg, Group V - Ethanolic extract of *Glinus lotoides* -400mg/Kg were administered by gavage four times at twelve hours breaks for the period of thirty hours. Group III- V animals were administered with rifampicin 1g/kg 30mts after first dose of test drugs. The standard drug (Silymarin) is used for screening hepatoprotective activity. After forty hours of rifampicin given, blood was collected from all sets of rats. The bloods were allowed to clot for forty five minutes at room temperature. Serum was isolated and it was used for various biochemical parameters – SGOT, SGPT, ALP and BILIRUBIN (Malloy and Evelyn method).

2.4 Histopathological Studies

One animal from every set was sacrificed and the liver was gathered for histopathology studies.

2.5 Statistical Study

The mean \pm SEM calculated for each parameter and one-way ANOVA was carried out followed by Dunnet's 't' test was used.

3. Results and Discussion

Phytochemicals play a vital role in humans. Phytochemicals play the leading role against several illnesses. Since the phytochemicals cure diseases without causing any harm to human beings, these can also be considered as “man-friendly medicines”⁸. Since the phytochemicals remedy infections without causing any hurt to human creatures, these can moreover be considered as “man-friendly medicines”. Phytochemicals are non-nutrient bioactive components that are fundamentally mindful for rummaging harmful radicals after oxidative stretch by producing cancer prevention agents, the most cause of most unremitting diseases⁹. Phenolic compounds gotten from normal sources are considered much more secure in terms of having no side impacts than synthesized chemicals¹⁰. The phytoconstituents present in hexane and ethanol extract were tabulated in Table 1.

Hexane extract of *Glinus lotoides* exhibited the existence of carbohydrate, protein, flavonoids. Ethanolic

Table 1. Preliminary phytoconstituents of different extract

S. No.	Phytoconstituents	Hexane Extract	Ethanol Extract
1	Protein	-	-
2	Alkaloids	-	+
3	Carbohydrates	+	+
4	Sterols	-	-
5	Glycosides	-	+
6	Flavonoids	+	+
7	Saponins	+	+
8	Tannins	-	+

"+" indicates presence of phytoconstituents; "-" indicates absence of phytoconstituents

Table 2. Hepatoprotective effect of *Glinus lotoides* Linn. on Rifampicin Induced Liver Impairment in Small Rodent

Design of Treatment	SGOT IU/L	SGPT IU/L	Alkaline Phosphatase (KA units)	Total (n) Bilirubin mg/100ml	Direct Bilirubin (mg/dl)	Indirect Bilirubin (mg/dl)
Control	31 ± 1.25	33 ± 1.25	23 ± 1.25	0.6 ± 0.17	0.25 0.065	0.3 0.1189
Negative control g/Kg	103 ± 1.25	155 ± 1.25	65 ± 1.25	1.8 ± 0.0285**	0.75 ± 0.0111**	1.06 ± 0.0287**
Silymarin 100mg/kg	45 ± 1.25*	32.5 ± 1.7*	27 ± 1.25**	0.7 ± 0.12**	0.25 ± 0.0125**	0.45 ± 0.6764**
EEGL 200mg/kg (Test)	54 ± 1.8 ^{ns}	47 ± 1.25 ^{ns}	43.5 ± 1.7**	1.6 ± 0.0395**	0.37 ± 0.0173**	1.18 ± 0.0347**
EEGL 400mg/kg (Test)	49 ± 1.1 ^{ns}	36.5 ± 1.7 ^{ns}	31 ± 1.25**	1.1 ± 0.12**	0.31 ± 0.0128**	0.79 ± 0.1244**
One way ANOVA [F]	21.6	122.9	164.8	26.5	83.3	15.8
df	4.15	4.15	4.15	4.15	4.15	4.15

Values are expressed as Mean ± SEM; n = 6; p<0.01***, P<0.001 ****, ns-non significant as associated to control group; one way ANOVA followed by Dunnett's t-test

extrication of *Glinus lotoides* Linn. exhibited the existence of glycosides, saponins, proteins, tannins, alkaloids, carbohydrate and flavonoids. Flavonoids, saponins are present in *Glinus lotoides* is coincides with result of Abebe Endale, *et al*¹¹. Flavonoids show a vital role in antimicrobial, antioxidant and other pharmacological activity¹².

Measurement of serum biological catalyst levels such as SGOT, SGPT, ALP and bile pigment has provided a powerful tool for studies of hepatotoxicity. Rifampicin treated animals showed elevated SGOT, SGPT, ALP and bilirubin levels as paralleled to normal study animal demonstrating liver impairment. Injection of ethanolic extract of *Glinus lotoides* at doses of 200mg/Kg P.O. remarkably reduce rifampicin induced elevation on the serum of SGOT, SGPT, ALP and bile pigment were shown in Table 2. These results were comparable with silymarin at a dosage of 400mg /Kg EEGL exhibited more significant anti-hepatotoxicity action when compared to the activities produced by 200mg/Kg dose.

The anti-hepatotoxicity action of these plants is based on bringing down liver biomarkers as well as smothering of breaking down changes in liver cells created by the Rifampicin compared with reference hepatoprotective medicate (silymarin) and control. The Rifampicin actuated liver impairment is interceded through oxidative harm to the hepatocyte, which caused the spillage of chemicals into vascular compartments and an increment within

the malondialdehyde substance which demonstrated the expanded the level of lipid peroxidation¹³. The treatment of EEGL both measurements was appeared made progresses liver histology. These impacts due to the plant have the antioxidant possibilities of flavonoids and other phenolic compounds, which may play the part in decreasing the Rifampicin - isoniazid induced free radicals within the rat liver¹⁴. The natural compounds with its antioxidant properties may play a part in assurance of the cells and tissues against harmful impacts of receptive oxygen species and other free radicals¹⁵.

Histopathological studies revealed the presence of liver normal architecture in normal control group (Figure 1a). Rifampicin treated group showed massive mononuclear cell infiltration, vacuolated cells and foam cells, necrosis, nodule formation with fibrosis, collagen deposit, and compression of portal tract engorged blood vessels (Figure 1c). Silymarin treated group showed hepatocytes arranged in normal form with blood vessels and showed the normalcy of liver structure (Figure 1b). EEGL at 200mg/kg treated group minimum mononuclear cell infiltration (Figure 1d) and normal staining nucleus showing very minimal hepatocyte damage at 400mg/kg treated group periportal fibrotic bands were not seen showing an almost normal architecture of liver (Figure 1e). Combined action of all the ingredients present in EEGL helps to normalize the liver functions and thus relieves liver disorder.

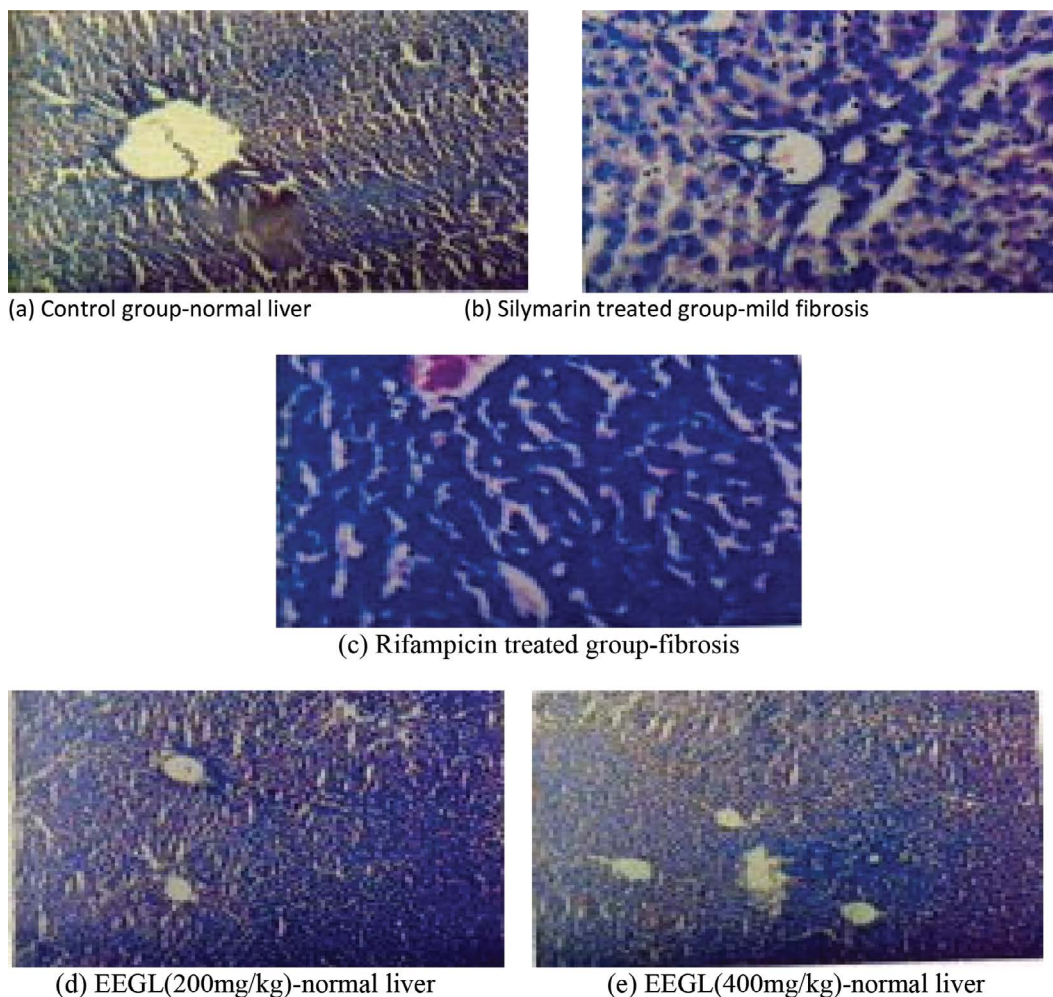


Figure 1. Histopathological examination of liver sections.

The hepatoprotective activities was appeared by bringing down within the serum biochemical parameters within the rifampicin inebriated rats pre-treated with ethanolic extricate at 200 and 400mg/kg. Histopathological evidence proved the anti-hepatotoxicity action in this plant extract.

4. Conclusion

From the results of pharmacological studies, we inferred that the two different dose extracts of *Glinus lotoides* showed dose development significant anti-hepatotoxicity action in albino rats. The anti-hepatotoxicity action of the plant extracts of *Glinus lotoides* was due to the presence of phytoconstituents which may reduce hepatotoxicity. These results after pharmacological evidence and support on the folkloric

use of *Glinus lotoides* leaves as a hepatoprotective agent. In conclusion, the ethanolic extract of *Glinus lotoides* exhibited few defensive impacts on the animal model studies show of rifampicin-induced hepatic harm. The prophylactic extricate of *Glinus lotoides* can be a potential source of hepatoprotective specialists. Advance separation of the dynamic standards capable for its hepatoprotective action is as of now in advance inside our research facility.

5. Acknowledgement

Authors are appreciative to the managing board and principal of V. V. V. College for Women, Virudhunagar, Tamil Nadu, India and SBCP, Sivakasi for making available amenities required to carry out this animal study.

6. References

1. Shaik Salma Suthana, Sai Kiran, Hareesh B. A Review on Herbal Medicines. *W. J. Pharm. Biotech.* 2018; 5(1):01-07.
2. Chandran M. FT-IR analysis of methanol extract of leaves of *Mollugo lotoides*. *JETIR.* 2015; 2(4):415-424.
3. Demma, *et al.* Toxicological study on *Glinus lotoides*: A traditionally used taenicidal herb in Ethiopia. *Journal of Ethnopharmacology.* 2007; 111(3):451-457. <https://doi.org/10.1016/j.jep.2006.12.017>
4. Amna Ehlasan Hamad Mohamed. Bioscreening of herbs with putative anti-ulcerogenic activity in rats. [PhD thesis]. 2010. <http://kharoumspace.uofk.edu/handle/123456789/8478>
5. Mengesha AE, Youan BB. Anti-cancer activity of extracts of the seed of *Glinus lotoides*. *J Nutri Sci vitaminol (Tokyo).* 2010; 56(5):311-8. <https://doi.org/10.3177/jnsv.56.311>
6. K Sudha Rameshwari, *et al.* Wound healing and antibacterial activities of the chloroform extract of *Glinus lotoides* Linn. In albino rats. *Int J. Pharm. Bio Sci.* 2013; 4(4):722-728.
7. JB Harborne. *Phytochemical methods: A guide to modern techniques of plant analysis*: Chapman and Hall Ltd., London. 1973; 279-279. https://doi.org/10.1007/978-94-009-5921-7_1
8. Sahira K Banu, Cathrine L. General Techniques Involved in Phytochemical Analysis. *International Journal of Advanced Research in Chemical Science.* 2015; 2:25-32.
9. Ahmad Al-Harrasi, Najeeb Ur Rehman, Javid Hussain, Abdul Latif Khan, Ahmed Al-Rawahi, Syed Abdullah Gilani, Mohammed Al-Broumi, Liaqat Ali. Nutritional assessment and antioxidant analysis of 22 date palm (*Phoenix dactylifera*) varieties growing in Sultanate of Oman. *Asian Pac J Trop Med.* 2014; 7(1):591-598. [https://doi.org/10.1016/S1995-7645\(14\)60294-7](https://doi.org/10.1016/S1995-7645(14)60294-7)
10. Kumar H, Bhardwaj K, Nepovimova E, Kamil K, Dhanjal DS, Bhardwaj S, Bhatia SK, Verma R, Kumar D. Antioxidant functionalized nanoparticles: A combat against oxidative stress. *Nanomaterials.* 2020; 10:1334. [Google Scholar] [CrossRef]. <https://doi.org/10.3390/nano10071334>
11. Abebe Endale, *et al.* Quantitative determination of the group of flavonoids and saponins from the extracts of the seeds of *G. lotoides*. *Journal of Chromatography.* 2005; 1083(1-2): 32-41. <https://doi.org/10.1016/j.chroma.2005.05.095>
12. Sudha Rameshwari K, Muthu Muneeswari M, Gloria Jemmi Christobel R, Mallika R, Renuka R, Salini R. Synthesis and evaluation of herbal formulation using natural extract. *Int. J. Res. Pharm. Sci.* 2020; 11(3):3450-3458. <https://doi.org/10.26452/ijrps>
13. Santhosh S, Sini TK, Anandan R, Mathew PT. Hepatoprotective activity of chitosan against isoniazid and rifampicin-induced toxicity in experimental rats. *European Journal of Pharmacology.* 2007; 572(1):69-73. <https://doi.org/10.1016/j.ejphar.2007.05.059>
14. N Delhiraj, MK Jaganathan, AR Vijayakumar. Evaluation of hepatoprotective effect of ethanolic extract of *Physali ixocarpa* against rifampicin-isoniazid induced hepatotoxicity in wistar rats. *Int. Res. J. Pharm.* 2020; 11(10):17-22. <https://doi.org/10.7897/2230-8407.111085>
15. Eidelman RA, Lamas GS, Hennerkens CH. The new national education program guidelines. Clinical challenges for more widespread therapy of lipids to treat and prevent coronary heart disease. *Achieve of Internal Medicine.* 2002; 162(18):2033-2036. <https://doi.org/10.1001/archinte.162.18.2033>