



# Treatment of Extra-gingival Pyogenic Granuloma (*Athara ratthathontham*) in Siddha – A Case Report

J. Jeyavenkatesh<sup>1\*</sup> and S. Roja Ramani<sup>2</sup>

<sup>1</sup>Kokila Siddha Hospital and Research Centre, Kunnanampatti Village, Thirumangalam, Madurai – 625706, Tamil Nadu, India; jeyavenkateshdrs@gmail.com

<sup>2</sup>Government Primary Health Centre, Poovanthi, Sivagangai – 630611, Tamil Nadu, India

## Abstract

The present case report was a 36-year female with lesion on the right side of inner lower lip and diagnosed as pyogenic granuloma occurring at an unusual site. The presently available treatment for pyogenic granuloma is surgical excision which might delay the wound healing due to complications such as intraoperative bleeding and post operative infection. Other treatment modalities such as cryosurgery, CO<sub>2</sub> and Nd:YAG lasers, flash lamp pulsed dye lasers, surgical ablation, and radiation may not be affordable for many patients. In our present study, the Siddha para-surgical therapy *chuttigai* (cauterization) was performed and the case was followed up for 30 days. The intervention was found to be as a simple, inexpensive therapy effective in treating small superficial pedunculated vascular lesions with no blood loss or no need of hospitalization.

**Keywords:** Cauterization, Chuttigai, Para-Surgery, Traditional Surgical Method, Siddha

## 1. Introduction

Pyogenic granuloma, a term coined by Crocker in 1903, is a frequently occurring non-malignant lesion of mucocutaneous origin<sup>1,2</sup>. This benign vascular tumour can also be referred by various other names such as pregnancy tumour, granuloma pyogenicum, granuloma pediculatum benignum, vascular epulis, and Hartzell's disease<sup>2</sup>. The term pyogenic granuloma is not associated with pus and histologically does not represent a granuloma<sup>3,4</sup>. There exists histological differentiation between Lobular Capillary Hemangioma (LCH) and non-LCH<sup>5</sup>. Pyogenic granuloma, when occurs on a rare location rather than gums such as inner part of the lip<sup>6</sup>, there is a critical need for its differential diagnosis, proper histopathology study, excision, and further management. The current study deals Siddha treatment of a case visited to Out-Patient Department complaints of a growth in the lower lip.

\*Author for correspondence

## 2. Case History

The presenting subject is a 36-year female with lesion on the right side of inner lower lip. The subject had noticed the negligible size lesion a month ago, and it was asymptomatic then. Over the time, it gradually increased in size causing discomfort while brushing the teeth and eating and used to bleed on trauma. The patient was unaware of any initial trauma caused by external injury or tooth bite at the site of the lesion. There was no past medical history of any other related illness and her oral examination did not reveal any abnormalities. She was moderately built, nourished well oriented, and vitals normal.

### 2.1 Physical Examination

She could open mouth adequately (up to 40 mm), blow air by convexing the lips. The lips were coral red in color, not

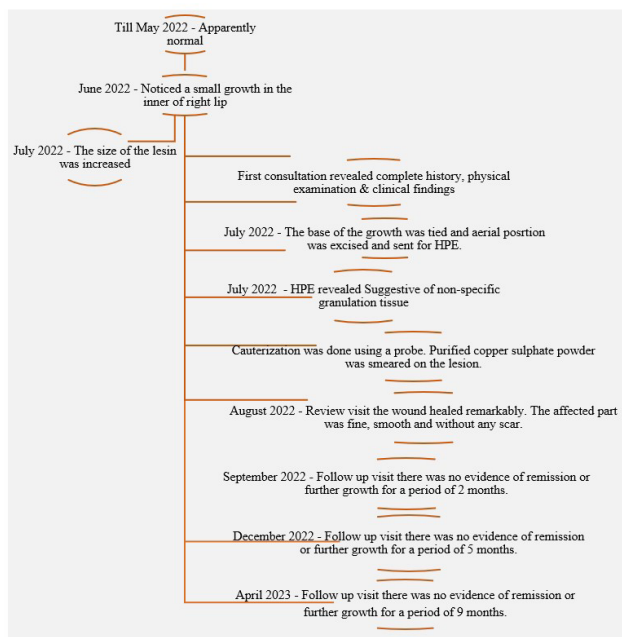
swollen, shrunken, cleft, deviated, and were closing each other perfectly. The tooth was not protruding in between the lips, lips were not marked by tooth bite, no rashes on the outer skin, and no growth found in upper lip. The right side of inner lower lip showed a lobulated red color flesh growth crowned by a white flesh. Other parts gum, teeth, tongue, lower jaw, upper jaw, upper lip, cheek, uvula, palate, throat, ear, and neck were examined for any swelling or palpable lymph nodes found insignificant.

### 2.1.1 Clinical Examination

Clinical examination revealed a pinkish exophytic, pedunculated growth measuring approximately 0.8 x 0.8 cm thick and 2.8 cm long, smooth lobulated surface in right side of the inner lower lip. The lesion was soft, non-tender, non-compressible, lobulated, and non-pulsatile. There were multiple bleeding points and the lesion was easily bleeding on hard touch, provisionally diagnosed as vascular lesion. A complete hemogram of the patient was unremarkable.

### 2.1.2 Timeline of the Disease and Treatment

A chronological arrangement of treatment from its first visibility, occurrence site, findings, investigations, treatment procedures, and follow up were listed in Figure 1.



**Figure 1.** Timeline of the disease and treatment.

### 2.1.3 Diagnostic Assessment

Clinically, it appeared as a smooth mass and exhibited a lobular architecture with peduncle. The larger amount of vascularity determined the pink color. There was no evidence of constant trauma either from the teeth or occlusion. Initial microtrauma by hard foods or forcible tooth brushing may have initiated the lesion. The genesis and development of the lesion may also be attributed to the other etiological factors such as the estrogen and progesterone effect on the vasculature. Histopathologic evaluation revealed that “A single grey brown tissue measures 0.5X0.5 cm, all embedded. The sections from biopsy show tiny bits of fibro collagenous tissue with extensive hemorrhage, necrosis and dense inflammatory cell infiltrate. The impression was suggestive of non-specific granulation tissue.” The differential diagnosis of hemangioma, peripheral ossifying fibroma, peripheral giant cell carcinoma was excluded<sup>7,8</sup>. The final diagnosis was Pyogenic granuloma, mainly based on the histopathological examination<sup>9</sup> and clinical findings.

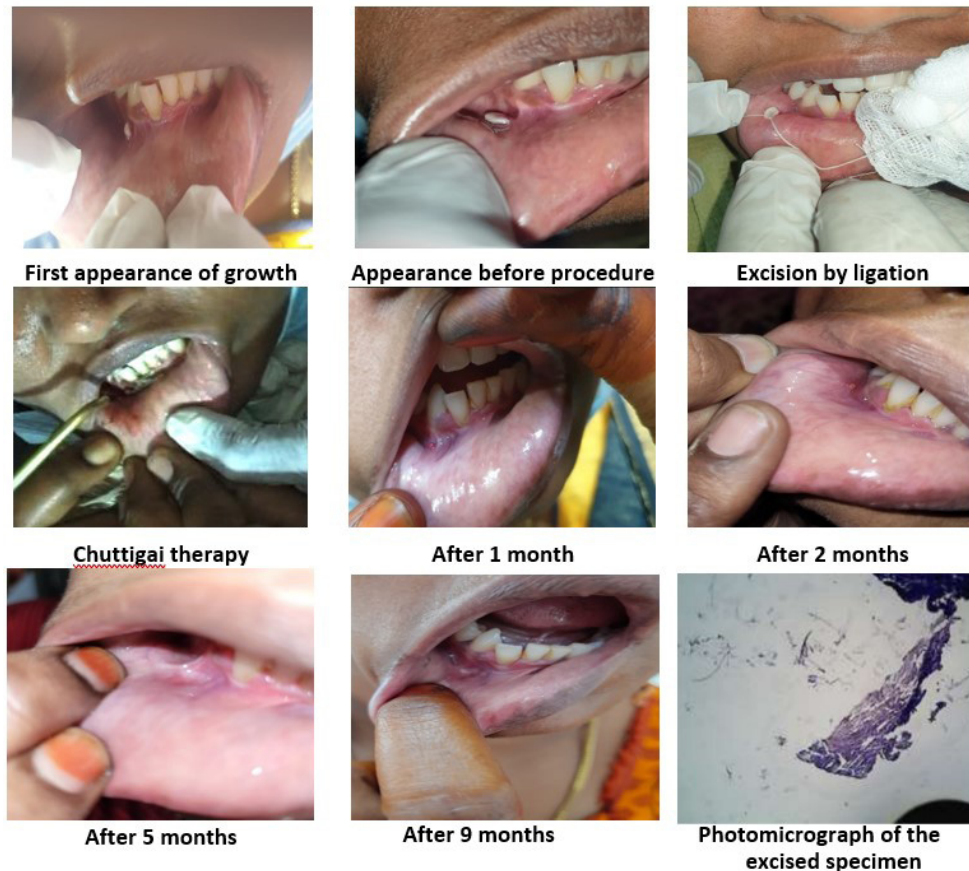## 3. Materials and Methods

### 3.1 The Following Are the Details of Instruments and Medicaments Used for The Procedure

- Chuttikai salagai* (*Agnikarma shalaka*) was purchased from *Panayu Panchakarma Ayurveda Shop*, Indore, Madhya Pradesh, India. It was properly sterilized and used for the procedure.
- Kadukkai* powder (Powder of *Terminalia chebula* dried fruit)<sup>10</sup>.
- Thurusu* powder (Fried Purified powder of copper sulphate)<sup>11,12</sup>.

#### 3.1.1 Biomedical Ethics

All biomedical ethics were followed and a voluntary written consent was obtained from the study subject for the publication of this case study with accompanying images. Pre-operative consultation and evaluation including overall health status of the patient, co-morbidities, vitals, complete blood count, anemia profile, bleeding, and clotting time, HbSag, HIV 1 and 2 were found to be unremarkable.



**Figure 2.** Treatment photos and histopathological photomicrograph.

### 3.1.2 Procedure

On the first visit, the mouth was washed with a decoction of *Thiripala churanam*. The base of the lesion was carefully tied using a barbour's surgical thread of size 40. Care was taken that the knot itself did not cut the lesion while tying. The free ends of the thread were cut about 1 cm above the knot. The upper portion of the stalk was carefully excised just above the knot using a surgical blade of size 11 and sent for HPE. Local anesthesia was not required. Dry freeze cotton packs were kept on the lesion for 15 mins to make sure there isn't any bleeding. *Kadukkai* (*Terminalia chebula*) fruit powder<sup>10</sup> was applied on the lesion and prescribed as topical application 4-6 times/day until review.

On the fourth day-the second visit, it was observed that the thread had fallen after one day of tying. One drop of gingelly oil was smeared on the lesion and a wet gauze piece was kept around it. A *Panchaloga* brass cauterizer was heated until the tip turned fire-red. The remaining lesion was carefully touched by the tip of the cauterizer for a fraction

of a second, and immediately a drop of gingelly oil was put on the lesion. The cauterization was repeated five times with an interval of 2-5 secs until the bleeding was arrested. 10 mg of purified *thurusu* (crystalline *copper sulphate*) powder<sup>11,12</sup> was applied on the lesion. The patient was advised not to give pressure or harm the lesion for at least two weeks.

On the review visit, the affected area was washed well with saline water, and it was observed that the wound had healed remarkably, inner part of the lower lip was fine and smooth without any scar. The treatment photos and histopathology photomicrograph are shown in Figure 2.

## 4. Results and Discussion

The patient was under surveillance. The follow-up after one month 4 weeks did not show any visible growth. A systematic process for review of the patient either by a direct visit or by a self-examination about the re-occurrence of any abnormal blue or purple vascular growth, bleeding on touch from the site, history of recent injury in the site, and

any palpable swellings in the nearby areas of mouth were recommended. She was advised to avoid local irritants or trauma to minimize the risk of recurrence.

Though poor oral hygiene may be the precipitating factor of pyogenic granuloma, extralingival pyogenic granuloma may result due to low grade local injury or irritation, vascular effects of hormonal changes during pregnancy and exposure to certain drugs<sup>13</sup>. Incidence of pyogenic granuloma is increased in pregnancy which is related to the increased level of estrogen and progesterone<sup>14,15</sup>. In present case, there was no history of injury. Even after surgical excision of pyogenic granuloma, some studies conclude a recurrence rate of 16%<sup>16</sup>, but it can be prevented<sup>17</sup>. Furthermore, most of these pyogenic granulomas are benign and slow growing<sup>18</sup>. A follow up of six months to one year is required or until menopause.

According to *Nagamuni Thalai Noi Marutthuvam* in Siddha system of Medicine, the three-humours, (*vatham*, *pittham*, and *silerpanam*) either individually or in combination with each other, develop *athara noigal* (lip diseases), which are classified into 16 types. They occur due to the impact of three-humours for the development of *thasai* (flesh), *rattham* (blood), *neer* (fluid), and *methai* (unctuous) in the lips. Among 16-types *athara ratthathontham* is more suitable and could be compared to pyogenic granuloma. In *athara ratthathontham*, three-humours develops black, red or yellow, and white color in flesh, numbness, ulceration, and purulent discharge in lip along with bleeding due to their surge concurrently. Although it is difficult to cure by oral medicine, *chuttigai* (cauterization) followed by an application of purified powder of *thurusu* would be beneficial as mentioned by Siddhar Nagamuni<sup>11</sup>.

According to modern science, pyogenic granuloma is a painless benign tumor with extreme vascularity causing bleeding and proliferation of skin and mucous membrane<sup>19,20</sup>. Gum is the predilection area other than the lip, tongue, and buccal mucosa. The disease is mostly prevalent in young adults and children<sup>21</sup> with female to male ratio of 2:1 possibly due to the vascular effects of female hormones<sup>22</sup>. The limitations of the present study are post-operative pain management, tissue necrosis and sloughing, oedema, and localized inflammations. The advantage of the therapy is simple, OPD procedure, no need of hospitalization, no blood loss, inexpensive, and the overall cost was below five hundred for whole procedure except the investigation's charges. Here,

*chuttigai* (cauterization) was the therapeutic intervention which is mentioned as para-surgical procedure in Siddha medical system. In this study, tying a thread controls any bleeding from cut lesion and allows the lesion to be shrunk and becomes avascular. After the thread has fallen, the *chuttigai* (cauterization) was done using a sterile *Panchaloga Chuttigai* instrument which was heated by an oil flame. In modern medicine, electro cauterization is done immediately after incision to arrest bleeding, but here, tying a thread allowed the lesion to become self-necrotized and followed by flame heated cauterization resulted in complete regression of the lesion without any pain, collateral anastomosis, and blood loss.

## 5. Conclusion

The presently available treatment for pyogenic granuloma is surgical excision<sup>23</sup>. Still, it might delay the wound healing due to complications such as intraoperative bleeding and post operative infection. Other treatment modalities such as cryosurgery, CO<sub>2</sub> and Nd:YAG lasers, flash lamp pulsed dye lasers, surgical ablation, and radiation<sup>24</sup> are also used in recent days, but they may not be affordable for many patients. *Uloga chuttigai* (Cauterization using metal) is one of popular therapy among 32 Siddha External therapies. Few cases affected from Osteo-arthritis were treated using *Chuttigai* therapy and documented<sup>25</sup>. The mechanism behind the hot metal cauterization and efficacy of *Chuttigai* therapy was already described<sup>26-28</sup>. Hence, it may be concluded that Siddha para-surgical therapy *chuttigai* (cauterization) is effective in treating small superficial pedunculated vascular lesions.

## 6. Authors Contribution

Jeyavenkatesh J was involved in Conceptualization, Methodology, Original draft preparation, Reviewing and Editing, and Roja Ramani S contributed in Data curation, Supervision, Investigation, Interpretation, Visualization, Validation, Formal analysis, Consent obtaining.

## 7. References

1. Shafer WG. Shafer's Textbook of Oral Pathology, 5<sup>th</sup> ed; 2006.
2. Jacoway JR. Pyogenic granuloma – Clinical features, incidence, histology, and result of treatment: Report of 242 cases. J Oral Surg. 1966; 24:391-8.

3. Patil K, Mahima VG, Lahari K. Extralingival pyogenic granuloma. *Indian J Dent Res* 2006; 17. <https://doi.org/10.4103/0970-9290.29864>
4. Regezi JA, Sciubba, James J, Jordan Richors CK. *Oral pathology: Clinical pathologic correlation*. St Louis Missouri: W B Saunders. Co., 4<sup>th</sup> ed; 2003.
5. Sternberg SS. *Diagnostic Surgical Pathology*, 3<sup>rd</sup> ed; 1999.
6. Kamal R, Dahiya P, Puri A. Oral pyogenic granuloma: Various concepts of etiopathogenesis. *J Oral Maxillofac Pathol*. 2012; 16(1):79-82. <https://doi.org/10.4103/0973-029X.92978>
7. Reichart PA, Philipsen HP. *Color atlas of dental medicine oral pathology*. Stuttgart: Thieme; 2000.
8. Wood NK, Goaz PW. *Differential diagnosis of oral and maxillofacial lesions*, 5<sup>th</sup> ed.; 1998.
9. AL-JA. Does histopathological examination still have value in detecting and preventing cancer? *Braz J Med Biol Res*. 2017; 5. <https://doi.org/10.17267/2317-3386bjmhh.v5i4.1372>
10. Ratnam KSV, Gunapadam MM. (*Siddha Materia Medica*), 2<sup>nd</sup> ed; 2006.
11. Thiyagarajan R. *Nagamunivar thalai noi maruthuvam*. 1<sup>st</sup> ed; 1976.
12. Arunvanan M, *et al*. Anti- microbial activity of “Thurusu thaivelai karukku” in the management of respiratory diseases; 2012.
13. Sangamesh NC, Poornima B, Vidya KC, Sakri SB. Extralingival pyogenic granuloma: A rare case report. *J Sci Soc*. 2013; 49-51. <https://doi.org/10.4103/0974-5009.109706>
14. Whitaker SB, Bouquot JE, Alimario AE, Whitaker TJ Jr. Identification and semiquantification of estrogen and progesterone receptors in pyogenic granulomas of pregnancy. *Oral Surg Oral Med Oral Pathol*. 1994; 78(6):755-60. [https://doi.org/10.1016/0030-4220\(94\)90092-2](https://doi.org/10.1016/0030-4220(94)90092-2)
15. Sachdeva SK. Extralingival pyogenic granuloma: An unusual clinical presentation. *J Dent (Shiraz)*. 2015; 16(3 Suppl):282-5.
16. Jafarzadeh H, Sanatkhanani M, Mohtasham N. Oral pyogenic granuloma: A review. *J Oral Sci*. 2006; 48(4):167-75. <https://doi.org/10.2334/josnusd.48.167>
17. Verma PK, Srivastava R, Baranwal HC, Chaturvedi TP, Gautam A, Singh A. Pyogenic granuloma - Hyperplastic lesion of the gingiva: case reports. *Open Dent J*. 2012; 6:153-6. <https://doi.org/10.2174/1874210601206010153>
18. Sarwal P, Lapumnuaypol K. Pyogenic granuloma. In: *StatPearls*. Treasure Island (FL): StatPearls Publishing; 2022. Available from: <https://www.ncbi.nlm.nih.gov/books/NBK556077/>
19. Plovonich M, Tsibris HC, Lian CG, Mostaghimi A. Giant pyogenic granuloma in a patient with chronic lymphocytic leukemia. *Case Rep Dermatol*. 2014; 6:227-231. <https://doi.org/10.1159/000367935>
20. Chikkaboraiyah S, Puttaswamaiah RN, Galgali SR. Pregnancy tumor. *J Health Sci Res*. 2016; 7(1):23-27. <https://doi.org/10.5005/jp-journals-10042-1029>
21. Mortazavi H, Safi Y, Baharvand M, Rahmani S, Jafari S. Peripheral exophytic oral lesions: A clinical decision tree. *Int J Dent*. 2017. <https://doi.org/10.1155/2017/9193831>
22. Arunmozhi U, Priya RS, Kadhiresan R, Sujatha G, Shamsudeen-SS SM. A large pregnancy tumor of tongue – A case report. *J Clin of Diagn Res*. 2016; 10(10):ZD10-12. <https://doi.org/10.7860/JCDR/2016/19869.8661>
23. Reichart PA, Philipsen HP. *Color atlas of dental medicine oral pathology*. Stuttgart: Thieme; 2000.
24. Azma E, Razaghi M. Laser treatment of oral and maxillofacial hemangioma. *J Lasers Med Sci*. 2018; 9(4):228-32. <https://doi.org/10.15171/jlms.2018.41>
25. Sridhar S. Efficacy of classical siddha external therapy “Suttigai” (Thermal Cauterization) on Azal keel vaatham. *J Dent Sci*. 2018; 17(9):1-11.
26. Dinesh BR, Prabakar K, Mahalakshmi V, Muthukumar NJ, Banumathi V. Suttigai [Cauterization] in Siddha system of Medicine. *Int J Curr Res Med Sci*. 2018; 4(1):166-9. <http://dx.doi.org/10.22192/ijcrms.2018.04.01.020>
27. Selvakumar M, *et al*. Role of heat shock proteins in Uloga Suttigai - A review. 2015. Available from: <https://www.researchgate.net/publication/305368410>
28. Rajalakshmi S, *et al*. A review on scopes, methods, and rationale of integrative approach in Siddha medicine with biomedicine. *Int J Pharm Sci*. 2020; 12(4):6-11. <https://doi.org/10.22159/ijpps.2020v12i4.36973>