

Magnetic Resonance Venography Proving its Utility and Standard over Clinical Findings in Diagnosing Cases of Cerebral Venous Thrombosis - A Case Series

Rajat Malhotra^{1*}, Abhay G. Kakade² and Nilesh Choudhari²

¹Clinical Associate, Sri Balaji Action Medical Institute, New Delhi, India; rajatmalh@gmail.com

²Associate Professor, Department of Radiology, Dr. Vasant Rao Pawar Medical College, Hospital and Research Centre, Nashik, India

Abstract

Introduction: Cerebral venous thrombosis is an uncommon disorder commonly seen in young, earlier this incidence was likely underestimated before the introduction of much accurate & non-invasive imaging modality. Now it has estimated that five to eight cases may be seen per year at a single tertiary-care center. Accurate and prompt diagnosis of cerebral venous thrombosis is crucial; because timely and appropriate therapy can reverse the disease process and significantly reduce the risk of acute complications and long-term sequelae. Since the possible causes and clinical manifestations of thrombosis are multiple and varied, imaging plays a primary role in the diagnosis. A wide range of cross-sectional imaging methods and venographic techniques can be used to detect abnormalities in the brain parenchyma as well as the cerebral veins and venous sinuses. **Materials and Methods:** In this study so far 50 patients have been prospectively taken with suspicion of intracranial vascular lesions & were referred to radiology department for MRI Brain with venography irrespective of age and sex. The study has been conducted taking up 50 patients as per the eligibility criteria with written informed consent. Siemens Magnetom Essenza 1.5 Tesla machine was used for the study. Multi-sequential study in coronal, sagittal and axial sections was taken. **Results:** This study provides a survey of common clinical findings in suspected cases of cerebral venous thrombosis and in several other disorders that may include a venous thrombotic process as a component. The normal venous anatomy has also been reviewed and potential pitfalls related to image interpretation are described. **Conclusion:** Finally it was concluded from this study, that majority of the patients diagnosed on MR imaging; were seen to be affected with intra-cerebral veins thrombosis. This study proves MR Venography as standard modality in establishing the early diagnosis of CVT in correlation with non-specific clinical findings.

Keywords: Cerebral Venous Thrombosis, Digital Subtraction Angiography, Diffusion Weighted Imaging, Hemorrhagic Infarcts, Intra-Cerebral Venous Sinuses, Time of Flight (TOF), Venography

1. Introduction

In last few decades there have been tremendous recent advances in development of Magnetic Resonance Angiography (MRA) for depicting vessels and blood flow as well as evaluating the occurrence of various cerebrovascular diseases.

In today's world there is possibility of covering extensive regions of vascular anatomy in a single breath hold. Though, most of advances have been made in field of arterial magnetic resonance angiography. On the other hand MRI of venous system of brain (based

on Susceptibility Weighted Imaging approach- SWI approach) is also important and offers new helpful insights into venous lesions and diseases, also has been seen that neurologists and neuro-radiologists are paying active attention to the role of Intracranial Venous System (ICVS) in cerebrovascular diseases.

Till now ICVS has been evaluated traditionally during venous phase of conventional catheterized Digital Subtraction Angiography (DSA) as gold standard investigation for analyzing intracranial venous anatomy and a definite diagnostic tool for intracranial venous pathologies. Although being a gold standard technique

DSA is still an invasive procedure with associated risks such as cerebral infarction, vascular wall injury and hematoma at puncture site¹. Radiation exposure, allergic or nephrotoxic effects of iodinated contrast medium, limitation of 2-Dimensional (2D) planar imaging are additional disadvantages.

Therefore, the use of non-invasive techniques is a need for evaluation of intravascular system. Various non-invasive techniques available are:

- CTV- Computed Tomographic Venography.
- MRV- Magnetic Resonance Venography.

CTV is more preferred over MRV due to its widespread availability and much faster image acquisition that reduces the patient related motion artifacts. However CTV is similar to catheter DSA due to need of iodinated contrast and radiation exposure; it also needs complex post-processing to remove bony structures from reconstructed images, thus visualization of skull base structures is limited. Therefore CTV provides more of supportive role than MRV; which is proved to be more reliable².

Also CTV provides false positive results in patients with-

- Empty Delta Sign.
- Filling defects.

Though MRV has some disadvantages like decreased spatial resolution, lower sensitivity and specificity for vascular patency, artifacts and potential diagnostic pitfalls.

Good correlation has been shown between MRV and DSA but there are 3 MRA methods commonly available for evaluating intravascular system:-

- 2-Dimensional (2D) Time of Flight (TOF)*.
- 3-Dimensional (3D) Phase-Contrast*.
- 3D Gadolinium-Enhanced (GE) Pulse Sequences.
- 2D TOF and 3D phase-contrast are the usually performed methods.

Cerebral Venous (CVT)/Cerebral Venous Sinus Thrombosis (CVST) has been recognized since the early 19th century but still remains a diagnostic and therapeutic challenge. Cerebral vein and sinus thrombosis is rare compared to arterial stroke that often occurs in young individuals³. CVT may occur at any time from infancy to old age most reported cases were women in association with puerperium. Onset of symptoms may be acute/sub-acute/chronic. Cerebral venous infarction is the most serious consequence of cerebral venous thrombosis, venous infarcts are often multifocal bilateral affecting

both grey matter and sub cortical white matter.

2. Aims and Objectives

- To study Magnetic Resonance Venography (MRV) findings in patients with clinical suspicion of intracranial venous thrombosis.
- Correlation between site of venous occlusion and associated clinical parameters.
- To study diagnostic utility of MRI Brain with venography in cerebral veno-occlusive diseases.

3. Materials and Methods

3.1 Materials

This study was approved by our institutional review board. In this study so far 40 patients have been prospectively taken with suspicion of intra-cranial vascular lesions and were referred to radiology department for MRI Brain with venography irrespective of age and sex.

3.1.1 Inclusion Criteria

Clinically suspected cases of intra-cranial vascular lesions that are referred to radiology department for MRI brain with Venography, irrespective of the age and sex.

3.1.2 Exclusion Criteria

Patients with history of metallic implant, foreign body, pacemaker, aneurysm clip, recently implanted prosthetic valve.

Patients who are unstable to undergo MRI (e.g.- patients on ventilator)

Claustrophobic patients.

Patients who are not willing to participate in the study.

3.2 Methodology

The study was conducted in MRI section of Department of Radio-diagnosis of Medical College and tertiary health care Centre. Total of 50 patients were included as per the eligibility criteria. Written informed consent was taken from all study participants.

The patients advised intracranial vascular study for suspicion of involvement of intracranial venous system were subjected to MRI of brain with Venography.

Siemens Magnetom Essenza 1.5 Tesla machine and a head coil were used for the study. Multi-sequential study in coronal, sagittal and axial sections was taken.

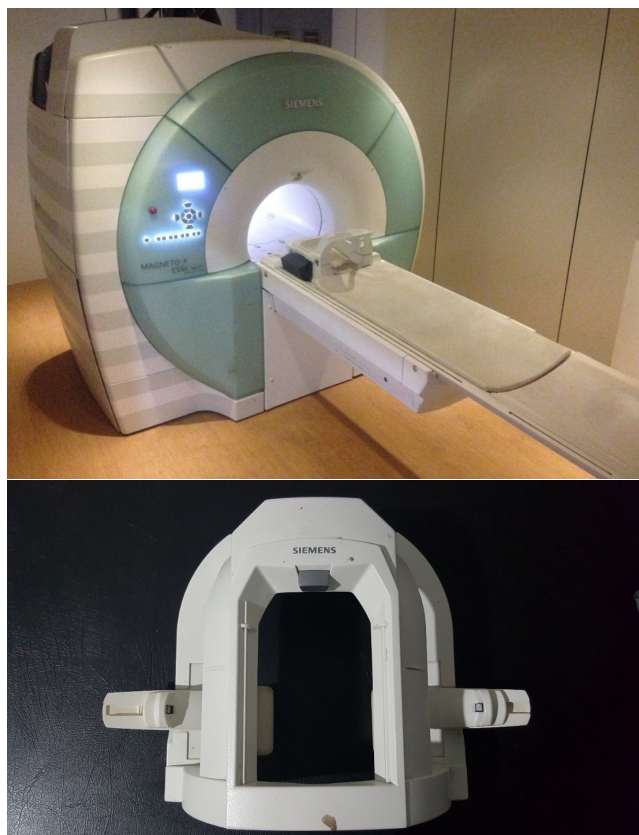


Figure 1. Demonstrating the 1.5 T MR machine and head coil utilized in the study.

The bio data, detailed clinical history followed by general physical examination and detailed central nervous system examination with examination of other significant systems, the outcome parameters from MRV findings are noted in pre-designed proforma.

These patients underwent MRI brain and venography which included use of T1WI, T2WI, FLAIR, T2*WI MRV, GRE- Hemo, DWI and ADC are used in diagnosis of sinus thrombosis and the parenchymal changes; 2D TOF MRA technique is used for venogram of cerebral sinuses. This study did not have gold standard Digital Subtraction Angiography (DSA) to be compared with. In house scans were done involving above mentioned sequences and intra-cranial venous structures were studied after standard reconstructions were prepared using Maximum Intensity Projection (MIP) and 180 degrees rotational reconstructions in coronal and axial planes with angle between images 10 degree.

In our study slice thickness for 2D TOF method was 3 mm with distant factor -33%. 2D TOF technique was optimized by choosing a sagittal slice orientation tilted slightly towards coronal and axial directions. The observations were compared by statistical method.

The appearance of intra-cranial venous structures was assessed in context of their signal intensity, uniformity and extent of dimension of the structure visible on three different Magnetic Resonance Venography (MRV) methods.

Structures forming deep venous system, included in study, are bilateral Internal Cerebral Veins (ICVs), bilateral Basal veins of Rosenthal (BVRs), bilateral Thalamostriate veins (TSVs), Vein of Galen (VG), Straight Sinus (SS), and Inferior Sagittal Sinus (ISS).

While structures from superficial venous system included in study are bilateral Veins of Trolard (VTs), Veins of Labbe (VLs) and among dural sinuses Superior Sagittal Sinus (SSS), bilateral Lateral Sinuses (LS), bilateral Sigmoid Sinuses (SGS), Torcular Herophili (TH). Posterior fossa veins and cavernous sinus were not considered for study as they are difficult to visualize with TOF, PC methods while with CE-MR it is possible to visualize cavernous sinus.

The thrombus within the sinus can be imaged with T1 and T2 weighted images or with MRV. In T1 and T2 weighted images the normal venous sinus shows flow void due to moving blood. In thrombosed sinuses the flow void is absent with varying signal depending on the age of thrombus and the sequences used. Absent signal with frayed appearance is a feature of thrombosis. Hypoplastic venous sinus, in plane effect, slow flow is some artefactual conditions for false positive finding. The parenchymal edema appears hyperintense in T2WI and FLAIR images. Venous infarcts appear hyperintense in T2 WI and FLAIR images. It is differentiated from edema by DWI which shows hyperintense regions. Hemorrhage can be intra-parenchymal or in subarachnoid space. Intra-parenchymal hemorrhage appearance in T1 and T2 images vary with the stage of hemoglobin breakdown. FLAIR sequence is highly sensitive for subarachnoid hemorrhage.

4. Results

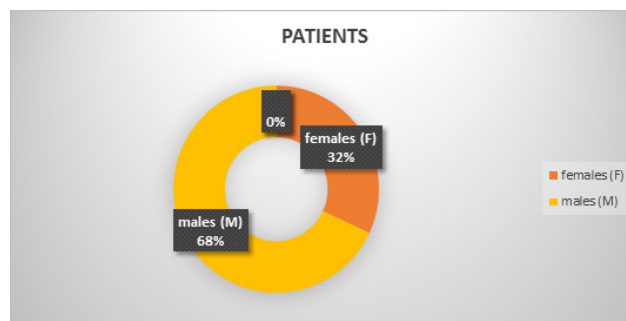


Figure 2. Distribution of patients according to sex.

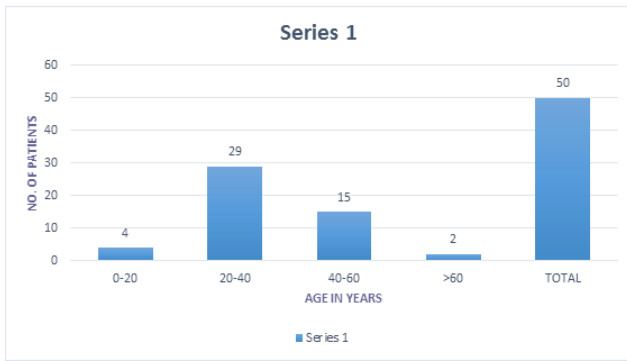


Figure 3. Distribution of patients according to age.

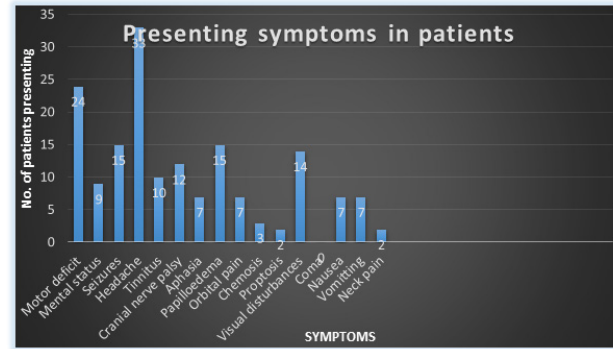


Figure 5. Distribution of clinical symptoms in patients.

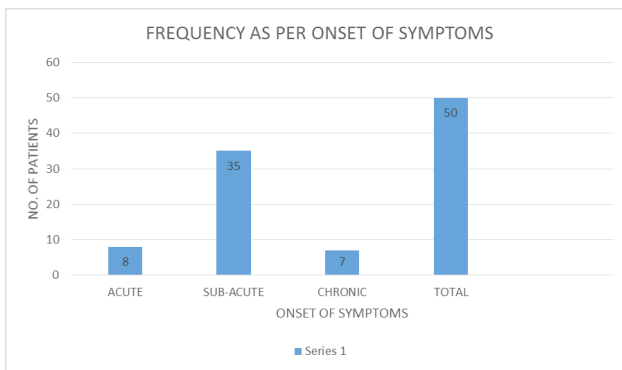


Figure 4. Distribution of patients according to duration of symptoms– mode of onset.

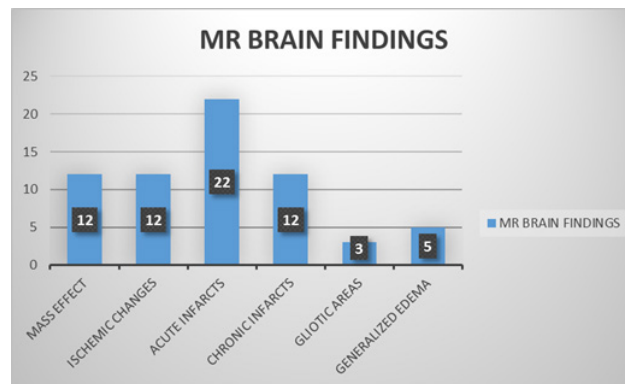


Figure 6. Distribution of MR brain findings in patients.

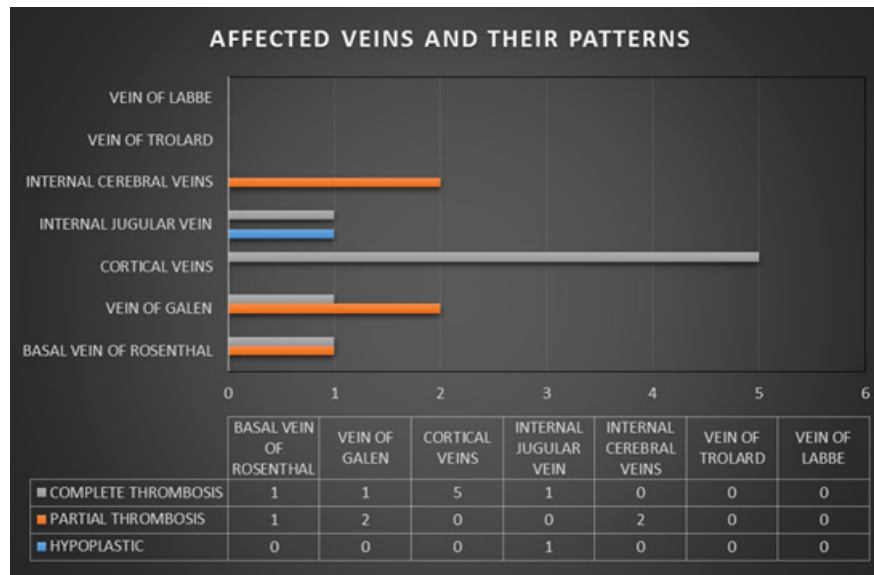


Figure 7. Distribution of affected veins.

Table 1. Distribution of sinus thrombosis involved

Sinus Involved	Right	Left	Anterior	Posterior	Thrombosis
SIGMOID (only 1 patient had bilaterally thrombosed sigmoid sinuses)	3 hypoplastic 11 thrombosed	1 hypoplastic 11 thrombosed	-----	---	----
STRAIGHT	-----	-----	----	----	2 thrombosed
TRANSVERSE (3 patients had bilaterally thrombosed sinuses)	1 hypoplastic 14 thrombosed	11 hypoplastic 15 thrombosed	----	-----	-----
SSS (16 patients presented with thrombosis of both ant. and post. segments)			19 thrombosed 2 partially 17 complete	19 thrombosed 2 partially 17 complete	

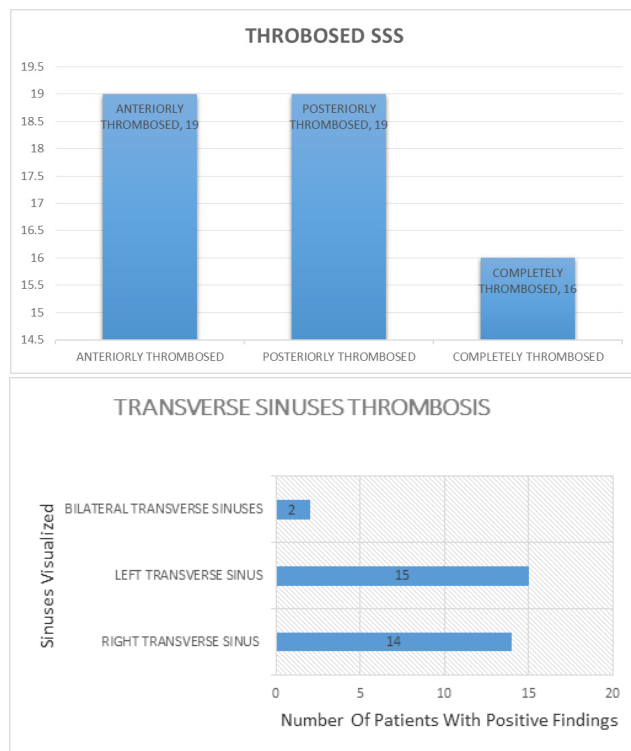


Figure 8. Distribution of superior sagittal & transverse sinus involved.

4.1 Results on the Basis of the Study Performed

The study included 50 patients with age range from 14 years to 72 years old as mentioned in statistical presentation with mean age of 35.60 years. Sixteen patients (32%) were female and thirty four patients (68%) were male. The most common and earliest clinical presentation in this study was headache followed by motor deficit, seizures, papilledema, visual disturbances, cranial nerve palsy, tinnitus, altered mental status, aphasia, orbital pain, nausea, vomiting, chemosis, and proptosis and neck pain/rigidity.

Among the predisposing factors for CVO were post-partum complications, followed by dehydration, trauma

and post-surgery complications; however, there was no obvious predisposing factor in few patients.

MRI features in this study were observed in the form of parenchymal changes and abnormal signals in thrombosed veins and sinuses in both T1 and T2, in addition to blooming and collaterals formation; however no patient with CVT was reported without any parenchymal changes on MR brain imaging.

These changes were seen in the form of acute hemorrhagic infarction in 22 patients, chronic hemorrhagic infarction in 12 patients, gliotic areas in 3 patients, mass effect in form of midline shift in 12 patients, ischemic changes in 12 patients and edema in 5 patients.

The most commonly seen MRI findings were replacement of the signal void of sinuses or veins by abnormal signal intensity; showing three patterns, the first was hyper intense signal in both T1 and T2 (i.e., late sub-acute stage), hyperintense signal in T1 and iso to hypo intensity in T2 (i.e., early subacute stage) while it was hypo intense signal in both T1 and T2 (i.e., chronic stage). Finally, there was one patient with equivocal signal in both T1 and T2 but was diagnosed by MRV.

The main MRV findings in our study were

- Non-visualization of occluded veins or sinuses due to absent signal.
- Flow defect.
- Presence of collaterals that may form in the dura that surrounds the occluded sinus.

These collaterals were noted in three patients in the study. MRV successfully diagnosed all cases.

The most common non-visualized sinus in the study group was SSS noted in 38%, followed by transverse sinus (30%), sigmoid sinus (22%) and straight sinus in (4%) the patients taken up for the study. 3 patients (6%) demonstrated the thrombosis of confluence of sinuses.

More than one sinus thrombosis or occlusion was found in majority of patients.

Both cortical and deep veins could not be visualized in 88% (44 patients from 50).

Finally it came out to be as a resultant factor that patients with occluded cerebral sinuses or veins had all/symptomatic neuro-parenchymal changes on MRI brain.

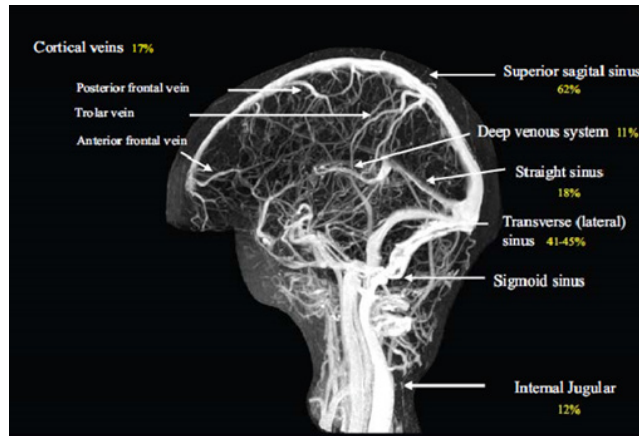


Figure 9. Showing the occurrence of thrombosis in various venous sinuses.

4.2 Correlation between the Site of Venous Occlusion and Clinical Parameters

Correlation with mode of onset showed no difference in onset whether sinuses alone vs deep venous vs combination of sinuses and veins.

No significant difference between presence of various sinuses and venous system, the presence and location of infarction.

When cortical veins are involved; patients were presented with seizures and have hemorrhagic infarct than when only sinuses were involved. Majority of the patients which presented with papilledema had isolated superior sagittal sinus or involved transverse sinus (ipsilateral/bilateral) involvement. Patients diagnosed with IJV thrombosis or hypoplasias have been noted to exclusively present with neck pain.

5. Discussion

Cerebral venous thrombosis is condition characterized by thrombosis of intracranial veins and sinus resulting in parenchymal damage and rise in intracranial pressure. Radiological hallmark is thrombosis of intracranial sinuses and veins with hemorrhagic infarction and edema with/without evidence of herniation. In this study, total 50 patients with clinical suspicion of cerebral venous thrombosis were evaluated over a period of 2 years. 34 out of 50 patients were males and remaining 16 were females. This study of 50 patients with CVT cannot give precise information about the real incidence of the disease. Study cannot make any generalization of the results.

Table 2. Clinical features of cerebral venous thrombosis in various Indian series and our study

CLINICAL FEATURES	BANSAL N = 138 (%)	SRINIVASAN N = 135 (%)	NAGRAJA N = 405 (%)	STUDY AT OUR IS-TITUTE N = 50 (%)
HEADACHE	48	24	70.8	66
VOMITTING	36	24	38	14
SEIZURES	23	36	35	30
DYSPHAGIA	25	5	-	24
VISUAL	-	-	11	28
DISTURBANCES	3	10	13	4
NECK PAIN	41	43	58	-
ALTERED SENSORIUM	28	15	24	18
ALTERED MENTAL STATUS	35	16	18.5	30
PAPILLEDEMA	69	49	66.4	48
MOTOR DEFICIT	-	-	-	20
	-	-	-	15
	-	-	-	24

It has been suggested that the incidence of CVT was higher in females and in the aged in other studies, this was not confirmed in the present series, in which Male: Female (34:16) this data is not consistent with previous Indian studies viz. Bansal et al (1980)⁴, Srinivasan et al (1983)⁵, Nagaraja et al (1987)⁶.

More than half of the patients of CVT evaluated were in the second to third decade of their age (29/50). The clinical presentation could be summarized in 3 main patterns, each of them simulating another neurological disease.

The present series confirms the fact that isolated single sinus involvement was less common than multiple sinuses involvement, in isolated sinus most frequently involved are SSS and TS Thus in most cases, occlusion involved at least two sinuses or sinus and cerebral veins. Among these, cortical veins were affected slightly more commonly than the deep venous system these frequent associations probably explain, at least partly, why good clinico-radiological correlations could not be established.

In this study, attempt was made to correlate the clinical profile with the topographic Radiological substrate like involvement of superficial/deep venous system or the pattern of infarction or outcomes of MR brain imaging. There was no significant correlation to evolve a pattern of diagnostic approach with significance, except in a few cases of multiple sinus involvement as in SSS with TS and other sinus or cerebral veins involved, correlating with radiological findings. However predictably, patients with deep venous system involvement and having ganglionic infarction had significantly less incidence of seizures. Patients with involvement of SSS had higher incidence of seizure and lower incidence of headache than those who didn't have SSS involvement.

As most of the patients had extensive involvement of cerebral sino-venous system, contribution of degree of involvement of anatomical structures to a particular clinical profile cannot be reliably predicted with higher precision.

The diagnosis of CVT is as difficult as its clinical

manifestations are non-specific and may be subtle. Several factors combine to create an extremely elusive diagnosis of CVT: wide spectrum of clinical presentations, various predisposing factors, and the fact that it affects individuals of all age groups⁷.

CVT may mimic various medical conditions as arterial stroke, tumor, encephalitis, abscess and idiopathic intracranial hyper-tension (pseudo tumor cerebri). So it is a diagnosis of exclusion and imaging investigation. Although most different modalities as DSA, CT, CTV and others help in diagnosis of Cerebral Venous Occlusion (CVO) but each one has specific side effects and some have normal findings⁸. Most of patients in this study were in the age groups of 14 years and 30–72 years. This agreed with similar literature reported that the most patients with this disease present in the young-to- middle-aged patients⁹. Other literature reported that it is most common in the third decade while it may occur in all age groups. A Canadian study was done on children in 2001 reported that CVST occurs in 10% in the first year of life and this is a lower percentage in comparison with the percentage in our study that reported three patients (20%) in the first year of life¹⁰.

The gender predilection of our study could not correlate with Einhaupl et al., that reported 75% of patients were females and had been suggested that the use of oral contraceptives in women is behind the disparity between the sexes. According to the complaints of patients presented with CVT or cerebral venous compression, the current study had shown that headache was the most frequent and often the earliest symptom noted in 33 patients (66%). This was in agreement with previous studies of Ameri and Bousser¹¹ who reported that 75% of the 110 cases complaint of headache.

The most common cause of cerebral venous occlusion in the current study was intraluminal thrombus, it occurred in 38 patients (76%) and this agreed with Bousser et al., who reported that all patients in his study of 110 cases had cerebral venous occlusion due to thrombosis. More than one feature may be present in one patient.

Table 3. Staging of thrombus on the basis or their MR imaging

Stage of thrombus T1WI	T2WI
Intensity Intensity	
Acute stage (22) Hyper Hypo	
Chronic stage (12) Hypo Hypo	
N.B. Two patients were with equivocal signal intensity in both T1 and T2 but were diagnosed successfully by MRV. 7 patients were diagnosed presenting with both acute and chronic thrombi.	

Edema was the most common parenchymal change found in the present study, seen in (13.13%) of cases but Simonds et al., observed focal edema in 25% of cases, followed by non-hemorrhagic infarction in (40%) and hemorrhagic infarction found in (26.7%). Nagaraj et al., found hemorrhagic infarction in (40.9%) and non-hemorrhagic infarction in (51.6%).

Twenty two patients (44%) in our study presented with acute thrombus. Twelve cases (24%) had chronic thrombus but two patient with equivocal signal. No cases of sub-acute thrombus could be detected. According to some estimates, in 10–30% of cases of sinus thrombosis, the thrombus at initial presentation or imaging examination is in the acute stage of formation. Acute-stage thrombus has been found in 55% of patients and this nearly agreed with our study and chronic thrombosis was found in 15% of patients^{12,13}.

In the current study, absence of signal intensity with consequent non-visualization of occluded sinuses or veins in the patients, flow defects in few and presence of collaterals in the rest. The superior sagittal sinus was most commonly involved accounting for (86.7%) and this agreed with Ameri and Bousser who reported in their study of 110 cases that SSS accounts for (72%). We finally concluded that MRI and MRV are valuable imaging modalities for the diagnosis of CVO especially as the clinical presentation and CT findings are usually non-specific. Therefore if it is suspected on CT; MRI and phase contrast MRV should be recommended as they are safer, non- invasive, non-ionizing and highly accurate modalities. Also phase contrast MRV has the ability to differentiate thrombosed sinuses from normal variants and other pitfalls^{14,15}.

6. References

1. Heiserman JE, Dean BL, Hodak JA, Flom RA, Bird CR, Drayer BP, et al. Neurologic complications of cerebral angiography. *AJNR Am J Neuroradiol.* 1994; 15:1401–7. PMID:7985557.
2. Agid R, Shelef I, Scott JN, Farb RI. Imaging of the intracranial venous system. *Neurologist* 2008; 14:12–22. PMID:18195652. <https://doi.org/10.1097/NRL.0b013e318157f791>
3. Bousser MG, Chiras J, Berics J, Castagne P. Cerebral venous thrombosis- A review of 38 cases. *Stroke.* 1985; 16(2):199–213. PMID:3975957. <https://doi.org/10.1161/01.STR.16.2.199>
4. Ein Haupl KM, Villringer A, Meister W, Mehracin S, Garner C, Pellkofer M, Haber RL, Pfister HW, Schmiedek P. Heparin treatment in sinus venous thrombosis. *Lancet.* 1993; 38:597–600.
5. Bansal BC, Gupta RR, Prakash C. Stroke during pregnancy and puerperium in young females below the age of 40 years as a result of cerebral venous /venous sinus thrombosis. *Jpn Heart.* 1980; 21:171–83. <https://doi.org/10.1536/ihj.21.171>
6. Nagaraja D, Taly AB, Puerperal venous sinus thrombosis in India. Sinha KK ed. *Progress in clinical neurosciences.* Ranchi: NSI Publications; 1989. p. 165–77. PMID:PMC184059
7. Khealani BA, Wasay M, Saadah M, Sultana E, Mustafa S, Khan FS, et al. Cerebral venous thrombosis: A descriptive multicenter study of patients in Pakistan and Middle East. *Stroke.* 2008 Oct; 39(10):2707–11. PMID:18635853. <https://doi.org/10.1161/STROKEAHA.107.512814>
8. Duddalwar VA. Multislice CT angiography: A practical guide to CT angiography in vascular imaging and intervention. *BJR.* 2004; 77:27–38. PMID:15546840. <https://doi.org/10.1259/bjr/25652856>
9. Ferro JM, Lopes MG, Rosas MJ, Ferro MA, Fontes J. Cerebral venous thrombosis portugese collaborative study group. Long-term prognosis of cerebral vein and dural sinus thrombosis. Results of the VENOPORT study. *Cerebrovasc Dis.* 2002; 13(4):272–8. PMID:12011553. <https://doi.org/10.1159/000057855>
10. Schievink WI, Maya MM. Cerebral venous thrombosis in spontaneous intracranial hypotension. *Headache.* 2008; 48:1511–9. PMID:19076649. <https://doi.org/10.1111/j.1526-4610.2008.01251.x>
11. Ameri A, bousser MG. Cerebral venous thrombosis. *Neuroclin.* 1992; 10:87–111. PMID:1557011.
12. Bergui M, Bradac G. Clinical picture of patients with cerebral venous thrombosis and patterns of dural sinus involvement. *Cerebrovasc Dis.* 2003; 16:211–6. PMID:12865607. <https://doi.org/10.1159/000071118>
13. Macchi PJ, Grossman JM, Goldberg HI, Zimmerman LT, Bilaniuk LT. High field MR imaging of cerebral venous thrombosis. *J Comput Assist Tomogr.* 1986; 10:10–5. PMID:3944291. <https://doi.org/10.1097/00004728-198601000-00002>
14. Simonds GR, Truwit CL. Anatomy of the cerebral vasculature. *Neuroimaging Clin Nam.* 1994; 4:691–706. PMID:7858916.
15. Villablanca JP, Rodriguez FJ, Stockman T, Dahliwal S, Omura M, Hazany S, et al. MDCT angiography for detection and quantification of small intracranial arteries: Comparison with conventional catheter angiography. *AJR Am J Roentgenol.* 2007; 188(2):593–602. PMID:17242273. <https://doi.org/10.2214/AJR.05.2143>